Degenerative Lumbosacral Syndrome in Dogs – surgical management strategies and new insights on outcome.

Thesis submitted to the University of Nottingham for the degree of Veterinary Science Master of Research

Sérgio Luís A.C.R. Gomes

Nottingham 2021

Supervisors

Mike Targett MA VetMB PhD DipECVN SFHEA MRCVS
RCVS & European Recognised Specialist in Veterinary Neurology
Clinical Associate Professor in Veterinary Neurology, University of Nottingham

Mark Lowrie MA VetMB MVM DipECVN MRCVS
RCVS & European Recognised Specialist in Veterinary Neurology

Abstract

Degenerative Lumbosacral Stenosis (DLSS) is a common debilitating condition affecting dogs, describing a multifactorial syndrome arising from the compression of the cauda equina and its associated nerve roots. Typically, cases present following a protracted history of suspected lumbar pain, persistent or episodic, made evident in activities where more force is loaded at the lumbosacral joint and its associated neuroforamina. Active, working, military or agility dogs are thought to be at risk of developing DLSS.

Diagnosis of DLSS relies on a compatible clinical history, exclusion of conditions with similar presentation and evidence of cauda equina compromise on diagnostic imaging. Cross-sectional imaging and particularly MRI are necessary to reach a DLSS diagnosis. A protracted, persistent or episodic history of lumbar pain, difficulties jumping and pelvic limb lameness, in the absence of overt orthopaedic disease, should alert the clinician that DLSS is possible.

Foraminal stenosis has been increasingly recognised as part of the DLSS syndrome, however previous to this thesis, decompressive surgery in clinically affected dogs had only been reported in a single study. Furthermore, alternative treatments to surgery in canine degenerative lumbosacral stenosis (DLSS) remain limited and reliable predictors of outcome are lacking.

This considered, this thesis aimed to: (1) review retrospectively the short and long-term outcome in a cohort of canine patients who underwent lateral foraminotomy in the treatment of lumbosacral foraminal stenosis, (2) assess the usefulness of a single epidural steroid injection (ESI) in the management of DLSS, (3) evaluate ESI as a predictor of outcome following decompressive surgery and (4) compare the outcomes of ESI and decompressive surgery. A set of hypotheses were proposed: (1) lateral foraminotomy would be a safe and useful treatment in cases of lumbosacral foraminal stenosis, (2) ESI can be effective in DLSS cases, leading to transient

alleviation of clinical signs, (3) ESI can be a reliable predictor of surgical outcome, e.g. a positive response to ESI can indicate a positive response to surgical decompression, (4) surgical decompression can lead to a more favourable outcome than a single ESI. In order to address these questions two studies, one retrospective and one prospective were developed.

For the first study, clinical records were reviewed retrospectively from 45 dogs which had undergone lateral foraminotomy at the lumbosacral junction either alone or in combination with decompressive midline dorsal laminectomy.

For the second study, dogs diagnosed with DLSS were prospectively recruited and administered an epidural steroid injection (ESI). If clinical signs persisted or relapsed, decompressive surgery was recommended. Follow-up was obtained.

Forty-five dogs were included in the retrospective study shown that short-term outcome at six weeks was assessed by the surgeon to be good (11.1 per cent) or excellent (88.9 per cent) in all 45 cases. Long-term outcome beyond six months for lumbosacral syndrome was assessed by the owner as excellent in all 34 cases for which follow-up was available despite recurrence in five cases. Recurrence of clinical signs was not related to re-establishment of foraminal compression at the surgical site when assessed on repeat MRI and was managed by either contralateral foraminotomy in one case or conservative management with excellent response.

Thirty-two dogs were recruited for the prospective study that underwent ESI, with seventeen having subsequent surgery. Improvement after ESI was seen in 27/32 dogs (84.4%), with 17/22 (77.2%) relapsing within 6 months. Five dogs failed to respond to ESI and another five dogs (15.6%) presented a persistent post-ESI favourable response (mean follow-up time, 9.4 months). Post-surgical improvement was identified in all dogs. Outcome was favourable following surgical decompression, with a statistically significant difference towards reduced pain, increased mobility, and a greater quality of life score. This study was not able to demonstrate that ESI could predict surgical outcome.

Concluding, the retrospective study confirmed lateral foraminotomy as an effective procedure in the management of DLSS-affected dogs suffering from foraminal stenosis and demonstrates that initial good short-term results are maintained long term despite some treatable recurrences.

Lateral foraminotomy is an effective procedure when used appropriately in DLSS with foraminal stenosis either alone or in combination with midline dorsal laminectomy.

The prospective study confirmed ESI as an effective treatment in most but not all cases, leading to transient alleviation of clinical signs for longer than previously reported. ESI also provided a complete and apparently long-term sustained resolution of clinical signs in a subset of dogs. Despite this, there was indication that surgical decompression could lead to a more favourable outcome. Epidural steroid injection has a role in the management of DLSS dogs, particularly when surgery is not an option.

DLSS remains a field of study in clinical veterinary neurology that requires extensive work in order to stablish a more definitive classification, treatment options and outcome measures. However, the results of this thesis appear to be clinically relevant, by means of confirming the efficacy of the lateral foraminotomy procedure in cases with foraminal stenosis, as well as demonstrating that ESI has a role in the management of DLSS.

Acknowledgements

I would like to thank both my supervisors Mark Lowrie and Mike Targett, for guiding me through my residency with real fairness, companionship and a real will to teach through example. You have both set very high standards that I would like to try and emulate in the future, as a veterinary specialist and particularly as a supervisor.

I would also like to thank everyone at Dovecote Veterinary Hospital – this is a really special place to work, a really big family that I found in the UK.

My father and grandfather, despite the distance, have always been there for me and supported me along the way and this is also for them. This is also to Sara, *a minha companheira*, that has helped and cared for me in this neurological journey almost since its beginning.

And this thesis is also in dedication to my little black Pekingese, *Pôti "A Princesa do Ave"*, which made me realise that neurology existed as a speciality, awakening something within me that lead me to choose this career path.

Abbreviations

DLSS	–	Degenerative Lumbosacral Stenosis
EMG	–	Electromyography
ESI	–	Epidural steroid injection
FS	–	Foraminal stenosis
IVDE	–	Intervertebral disc extrusion
Kg	–	Kilogram
LF	–	Lateral foraminotomy
LTV	–	Lumbosacral transitional vertebra
MRI	–	Magnetic Resonance Imaging
STIR	–	Short T1 Inversion Recovery
T1W	–	T1-Weighted
T2W	–	T2-Weighted

Table of Contents

Abstract ii

Acknowledgements v

Abbreviations vi

List of tables 1

List of figures 2

Publications and Presentations 5

Chapter I: Review of DLSS in dogs 6

1 Introduction 7

1.1 Relevant anatomy involved in DLSS 7

1.1.1 Neural structures: spinal cord and *cauda equina* 8

1.1.2 Anatomy encompassing neural structures 8

1.2 Pathophysiology 10

1.2.1 Causative pathologic or degenerative processes 12

1.2.2 Mechanisms of neural injury and neuropathic pain 13

2 Clinical features of DLSS 14

2.1 Signalment 14

2.2 Presenting complaints & typical clinical signs 15

2.3 Neurological examination findings 17

2.4 Differential diagnosis 19

3 Diagnosis of DLSS 19

3.1 Plain radiography 19

3.2 Contrast radiography: myelography, discography and epidurography 22

3.3 Computed tomography 22

3.4 Magnetic resonance imaging 23

3.5 Other diagnostic modalities 23

3.5.1 Electrophysiologic studies 23

3.5.2 Epidural steroid injection 24

4 Syndromes within a syndrome **24**

4.1 Vertebral or central canal stenosis **25**

4.2 Foraminal stenosis (uni or bilateral) **27**

4.3 Lumbosacral dynamic compression & suspected instability **29**

4.4 Congenital vertebral malformations **30**

4.5 Other non-DLSS compressive conditions **32**

5 Treatment options for DLSS **32**

5.1 Conservative management **32**

5.2 Epidural-steroid injection **32**

5.3 Surgical management **34**

5.3.1 Dorsal laminectomy **35**

5.3.2 Lateral foraminotomy **38**

5.3.3 Stabilisation and distraction techniques **39**

6 Preparatory work **40**

7 Aims of the Thesis **41**

Chapter II: Materials and Methods **42**

1. Retrospective study: Long-term outcome following LF as treatment for DLSS in dogs **43**

1.2 Advanced Imaging **45**

1.3 Surgical procedures **48**

14 Outcome and recurrence **48**

2. Prospective study: Single dose epidural steroid as a treatment and predictor of outcome following subsequent decompressive surgery in DLSS with FS **50**

2.1 Study design **50**

2.2 Diagnosis and ESI **51**

2.3 Surgical decompression **52**

2.4 Outcome **52**

2.5 Statistical analysis **52**

Chapter III: Results **54**

1 Retrospective study **55**

1.1 Signalment and history **55**

1.2 Pre-operative treatments **55**

1.3 Surgical procedures and complications **55**

1.4 Short-term outcome **56**

1.5 Long-term outcome **56**

2 Prospective study **59**

2.1 Animals **61**

2.2 Outcome and statistical analysis **61**

Chapter IV: Discussion **67**

1. Retrospective study **68**

2. Prospective study **72**

Chapter V: Conclusions **77**

1. Conclusions **78**

2. Future directions **78**

Supplementary material **79**

1. Supplement 1 ..... **79**

2. Supplement 2 ..... **81**

3. Supplement 3 ..... **83**

References **85**

List of tables

Table 1:1	Structures and pathological processes amenable to cause DLSS	11
Table 1:2	Differential diagnosis and common confounders of DLSS. Adapted from Meij and Bergknut 2010, Sjöström 2003.	21
Table 2:1	Classification of dogs according to severity of clinical and neurological Signs. Adapted from De Risio et al. 2001 and Gödde and Steffen 2007.	44
Table 2:2	Detailed clinical outcome (prospective study).	63
Table 2:3	Detailed owner perceived outcome for dogs having both ESI and decompressive surgery (prospective study).	64

List of figures

Figure 1:1	A Doberman exhibiting a toe touching posture. DLSS cases characterised by nerve entrapment or impingement (foraminal stenosis) can present with a toe-touching or nerve root signature posture, were the effected limb is not fully supported on the ground whilst the animal is standing. This could translate positional root-related pain or possible uncomfortable sensations (pricking, tingling or numbness) when supporting the limb	16
Figure 1:2	Distribution of owner presenting complains of 48 dogs affected with DLSS, diagnosed at Dovecote Veterinary Hospital (2017-2019).	18
Figure 1:3	Lateral recess (indicated by arrows) are the osseous tubular passageway where the L6 (white arrow, less pronounced) and L7 (black arrow, more pronounced) nerves run before leaving the vertebral canal. The lateral recess forms the entrance zone of the lateral foramen continuing into the middle and exit zones.	26
Figure 1:4	T2-weighted transverse MRI image (A) and CT transverse section (B) with a bone algorithm at the level of the L7-S1 intervertebral disc, demonstrating foraminal zones: (a) entrance zone , (b) middle zone, (c) exit zone. The extraforaminal zone is represented by the letter (d). Based on Gödde and Steffen 2007.	28
Figure 1:5	Computed tomography in the dorsal plane using a soft tissue algorithm centered at the level of the lumbosacral joint in two dogs. Both CT images demonstrate sacralization of L7, characterized by malformation of a transverse process, with abnormal fusion with the ilium wings.	31

Figure 1:6 Dorsal view of the lumbosacral joint (A), revealing the dorsal laminectomy approach with preservation of the articular facets. Lateral view of the lumbosacral joint (B1, B2) comparing the size of intervertebral foramen in a non-operated dog (B1) and following lateral foraminotomy (B2). 37

Figure 2:1 T2W parasagittal images of a dog with right unilateral foraminal stenosis. White arrows indicate the intervertebral foramina. An almost complete fat signal loss is noticeable in the affected foramen (A). Foraminal stenosis can be observed more clearly when affected (A) and non-affected (B) foramina are compared. 46

Figure 2:2 T2W transverse (A) and dorsal STIR (B) images of a dog with right unilateral foraminal stenosis. Subjective L7 nerve swelling on the affected site can be observed on both images, indicated by white arrows. Hyperintensity obtained on dorsal STIR (B) is notable when compared to contralateral unaffected foramen. 47

Figure 3:1 Pre-operative dorsal STIR (A1), T2W transverse (B1), T2W parasagittal (C1) and 22 months postoperative dorsal STIR (A2), T2W transverse (B2), T2W parasagittal (C2) of a dog with right unilateral foraminal stenosis. Right nerve root swelling is noticeably decreased 22 months following surgery (white arrows); however, it is still subjectively enlarged when compared with the contralateral nerve root. Right foraminal stenosis (white arrow) is clearly noticeable previously to surgery (B1) being resolved following surgery (B2). Lateral foraminotomy post-surgical borders are clearly identified (C2) with no evidence of reestablishment of 58

stenosis. This patient underwent a right-sided lateral foraminotomy, with recurrence of clinical signs 22 months following surgery. Right foraminal stenosis was not proven to be re-established and following conservative management, complete resolution of clinical signs was achieved.

Figure 3:2 Diagram depicting the clinical trial sequence, included patients and reasons for exclusion (prospective study). 60

Figure 3:3 Box and whiskers plots representing owner perceived pain, mobility and quality of life scores of the whole population (n = 32) at two time points, initial and following epidural steroid injection (ESI). Circles beyond the whiskers indicate outliers, with asterisks identifying extreme outliers. 65

Figure 3:4 Box and whiskers plots representing owner perceived pain, mobility and quality of life scores of the dogs receiving surgery (n = 17) at three time points, initial, following epidural steroid injection (ESI), and following surgery decompression. Circles beyond the whiskers indicate outliers, with asterisks identifying extreme outliers. 66

Publications and Presentations

Papers

- Gomes SA, Lowrie M, Targett M. Long-term outcome following lateral foraminotomy as treatment for canine degenerative lumbosacral stenosis. Veterinary Record. 2018 183, 352.
- Gomes SA, Lowrie M, Targett M. Single dose epidural methylprednisolone as a treatment and predictor of outcome following subsequent decompressive surgery in degenerative lumbosacral stenosis with foraminal stenosis. The Veterinary Journal. 2020 Mar 30:105451.

Conference proceedings

2017 Gomes SA, Lowrie M, Targett M. Lateral foraminotomy as treatment of lumbosacral foraminal stenosis in forty-five dogs with degenerative lumbosacral stenosis. Proceedings of 30th Annual Symposium of the European Society of Veterinary Neurology, Helsinki, Finland, September 21st-23rd.

2018 Gomes SA, Targett M, Lowrie M. Translaminar epidural methylprednisolone injection as predictor of short-term surgical outcome following decompressive surgery in degenerative lumbosacral stenosis. Proceedings of 31st Annual Symposium of the European Society of Veterinary Neurology, Copenhagen, Denmark, September 20th-22nd.

Chapter I

REVIEW OF DEGENERATIVE LUMBOSACRAL STENOSIS IN DOGS

1 Introduction

Degenerative Lumbosacral Stenosis (DLSS) is a common debilitating condition affecting dogs of all ages and sizes, being the most common cause of cauda equina syndrome (De Risio 2000). DLSS describes a multifactorial syndrome where alterations to the structures surrounding the cauda equina and its associated nerve roots, lead to clinical signs, by means of direct compression or compromise of its vascular supply (De Risio 2000, Sharp and Wheeler 2005, Meij and Bergknut 2010). A plethora of terms have been historically utilised describing this condition in dogs including cauda equina syndrome, lumbosacral spondylopathy, lumbosacral stenosis, lumbosacral malformation malarticulation, degenerative lumbosacral stenosis (DLSS), lumbosacral disease and lumbosacral spondylolisthesis (De Risio 2000). However, since initially suggested by Chambers (Chambers et al.1988, Chambers 1989) the term DLSS took its hold as the nomenclature describing this syndrome and will therefore be the terminology utilised throughout this dissertation.

The aetiology of DLSS relies on the gradual encroaching or impingement of the cauda equina and its associated nerve roots. As it progresses chronic damage to the nerves can cause hypersensitisation and pain, leading to a panoply of clinical signs. The strict definition of DLSS entails compression of the cauda equina and any of its composing nerve roots, lumbar (L6, L7) and sacrocaudal (S1-S3 and Cd1-Cd5). However, in the clinical setting, compression is most commonly found at the level overlying the L7-S1 intervertebral disc causing compression of the L7 and sacral nerves, as well as at the level of its neighbouring foramina as both L7 nerve roots leave the vertebral canal (Harcourt-Brown et al. 2019). Therefore, a particularly focus throughout this thesis will be kept in the description of this particular area.

1.1 Relevant anatomy involved in DLSS

1.1.1 Neural structures: spinal cord and *cauda equina*

The canine spinal cord is divided into cervical (8), thoracic (13), lumbar (7) and sacral (3) spinal segments, each giving rise to a corresponding pair of spinal nerves. During normal embryologic development, a disparity between the length of the spinal cord and the vertebral column means that only a few spinal segments are actually within the corresponding vertebrae, at the level of the thoracolumbar junction between T11-L2. This disparity is more pronounced in the caudal lumbar and sacrocaudal segments, where an increasing distance has to be covered by the corresponding spinal nerves before their exit from the vertebral canal. Lumbar nerve roots are numbered according to the intervertebral foramen of exit and the vertebra cranial to it. (Evans and De Lahunta 2013)

The location of the conus medullaris (where the spinal cord terminates) varies within different breeds, most commonly located over the L6-L7 intervertebral disc space, with a tendency to be found more caudally in smaller breed dogs (Fletcher and Kitchell 1966, Evans and De Lahunta 2013). This is clinically relevant as the spinal cord should typically not be compromised in DLSS.

The cauda equina is a bundle of lumbar (L7) and sacrocaudal (S1-S3 and Cd1-Cd5) spinal roots originating from the conus medullaris (where the spinal cord terminates), extending over the vertebral body of L6 to Cd5 (Indrieri 1988; Evans and De Lahunta 2013). The cauda equina nerve roots are contained within the vertebral canal, exiting the vertebral canal through intervertebral foramina.

1.1.2 Anatomy encompassing neural structures

The canine vertebral column is divided into cervical (7), thoracic (13), lumbar (7), sacral (3) and caudal (6-23) vertebrae. The caudal lumbar vertebrae (L5-L7), present cranially and slightly

ventrally oriented transverse processes, with L6 and L7 not typically presenting accessory processes (Evans and De Lahunta 2013). The articular processes restrict lateral flexion, with the caudal processes being present medially between the cranial processes of succeeding vertebrae. A pair of dorsal synovial facet joints occur at the junction of the articular processes of contiguous vertebrae, also called *articulations processuum articularum* or *juncturae zygapophyseales.* The intervertebral foramina are laterally positioned (Evans and De Lahunta 2013).

The sacrum develops as a single unit made by the fusion of S1, S2 and S3, contained and articulating with the ilia. The sacral intervertebral foramina are dorsally and ventrally positioned (Evans and De Lahunta 2013). The caudal vertebrae present a considerably more variable anatomy than other regions and are not typically found involved in DLSS.

The neural structures are contained within the vertebral canal, formed by consecutive vertebrae. The vertebral canal is considerably narrower following the lumbosacral joint.

The L7-S1 intervertebral disc is the largest disc of the canine spine, forming an important part of the lumbosacral joint. The lumbosacral or L7-S1 joint is subject to more strain and motion than other more cranial lumbar joints (Meij et al. 2007).

The vertebral canal has a supportive ligamentary system, the most relevant in DLSS being both the interarcuate ligament (or *ligamentum flavum*) and the dorsal longitudinal ligament. The *ligamentum flavum* lies dorsal to the neural structures and the dorsal longitudinal ligament is contained between the intervertebral disc and the epidural space.

An intervertebral foramen, also termed lateral foramen, is formed by two consecutive vertebrae. The L6-L7 and L7-S1 intervertebral foramina are found to be the most relevant in DLSS. Intervertebral foramina are divided into an entrance, middle and exit zones (Figure 1:4) (Gödde and Steffen 2007). The lateral recess forms the entrance zone of the lateral foramen continuing into the middle and exit zones. Several structures travel through the lumbosacral intervertebral foramen including the lumbar intervertebral vein with its several smaller suppliers, the spinal

branch of the lumbar artery (or radicular artery) and a spinal nerve root, all surrounded by a substantial quantity of periradicular fat (Breit et al. 2013). The L7 dorsal root ganglion is contained within the intervertebral foramen.

1.2 Pathophysiology

The lumbosacral joint is subject to significant motion, strain and transfer of forces, being prone to "wear-and-tear". Consequently, degenerative changes to the structures surrounding neural structures accumulate overtime. Examples of several structures and pathologies involved in DLSS are described on Table 1-1.

Structures and pathological processes amenable to cause DLSS
L7-S1 intervertebral disc • Intervertebral disc herniation (protrusion) **Vertebral body** • Osteophyte formation • Osteochondrosis • Lumbosacral transitional vertebrae **L7-S1 articular facet** • Synovial cysts • Congenital malformation **Interarcuate ligament (*ligamentum flavum*)** • Thickening / fibrosis **Dorsal longitudinal ligament** • Thickening / fibrosis **Filum terminale** • Tethered cord syndrome **Vasculature** • Congestion / compression / thrombosis / malformation **Epidural fat** • Fibrosis • Idiopathic sterile inflammation

Table 1:1: Structures and pathological processes amenable to cause DLSS

1.2.1 Causative pathologic or degenerative processes

Compression of neural structures in DLSS is typically chronic, through static or dynamic processes. Nerve roots are affected by a multitude of compressive processes

Despite the presence of distinctive characteristics of typically involved vertebrae (L6 to Cd5), degenerative processes affecting these are not effectively distinct from processes affecting other portions of the vertebral column. Compression develops through degenerative processes of the bone by means of osteophyte formation or an abnormal congenital morphology of the vertebrae.

An L7-S1 intervertebral disc protrusion is commonly found in dogs even in the absence of clinical signs (Axlund and Hudson 2003). Intervertebral disc protrusion or Hansen Type-II disc herniation is a degenerative process characterised by a deviation of the nucleus pulposus through a partial ruptured and weakened annulus fibrosus (Brisson 2010). The formation of protrusions at the level of the lumbosacral joint appears to be exacerbated by its greater mobility relating to other lumbar joints. Compression secondary to an L7-S1 intervertebral disc protrusion usually spares the L7 nerves that do not directly overly this intervertebral disc.

Soft tissue alterations are also possible, such as ligamentum flavum hypertrophy or synovial cysts. Ligamentum flavum hypertrophy can be found, causing dorsal compression of the cauda equina (Jones et al.1999).

Degenerative joint disease occurring at the level of articular facets joints throughout the vertebral column is commonly observed radiographically and during necropsy examination in clinically non-affected dogs (Schwarz et al. 2000). However, compression to the cauda equina appears to arise by the formation of intraspinal articular cysts, histologically defined as either synovial or ganglion cysts (Webb et al. 2001). At the level of the lumbosacral region this has been described as causative of DLSS in 9 cases, with or without concomitant vertebral malformations (Webb et al. 2001; Sale et al. 2007; Forterre et al. 2006; Schmökel et al. 2016).

Although rarely reported as causative of DLSS, a single instance of an L5-L6 arachnoid diverticulum and a L6-L7 meningeal cyst have been reported in two French Bulldogs (de Nies et al. 2018).

Foraminal stenosis is defined as a discrepancy between the foramen and its contents, where compression of the lumbar nerve roots occurs secondary to changes within components forming the foramen and surrounding it (Gödde and Steffen 2007, Breit et al. 2013).

1.2.2 Mechanisms of neural injury and neuropathic pain

The progressive compression of the cauda equina within the vertebral canal, associated lateral foramina and blood supply cause changes within the affected roots. Persistent compression of the nerve root causes an elevated intraneural pressure which associated with impaired perfusion can lead to irreversible changes. Compression of the nerve root results in impaired venous and lymphatic drainage resulting in endoneural oedema (Yoshizawa et al. 1995). Interstitial and perivascular fibrosis then ensues, contributing to irreversible nerve root enlargement (Lindahl 1951). Significant thickening of the nerve root is commonly found on DLSS cases, by means of hyperplastic fibrosis and inclusion of Renaut bodies. Despite the lack of literature on the subject in canine DLSS, inflammatory changes appear to not be a common histologic feature of nerve roots chronically affected by foraminal stenosis (Matiasek et al. 2008).

A discussion about the origin of lumbosacral pain in dogs, a hallmark of DLSS is required. Nociceptors ("pain receptors") are present in several tissues and noxious stimuli are transmitted through sensory afferent fibers entering the spinal cord via the dorsal root, synapsing in the dorsal horn. Conscious perception is obtained following the transmission of this noxious stimuli to the somatosensory cortex via several ascending pathways extending along the several spinal funiculi and the thalamus (De Lahunta et al. 2015, Thomson and Hahn 2012). In man, tissues capable of

transmitting pain at this level include intervertebral discs, facet joints, ligaments, fascia, muscles, and the nerve root *dura mater* (Kuslich et al. 1991). In dogs, discogenic pain has been implicated in lumbar pain and discectomy has been advocated in the alleviation of pain associated with annular protrusion (Danielsson and Sjöström 1999). Dorsal root ganglia, aggregates of cell bodies of afferent sensory neurons, are contained within the L7-S1 intervertebral foramen. Compromise of these ganglia can lead to neuropathic pain by means of disinhibition of interneurons in the dorsal horn (Baron et al. 2010), also overexpression of calcium channel receptors (subunit alpha-2-delta), substance P and calcitoning gene-related peptide have been reported in these ganglia in DLSS affected dogs (Matiasek et al. 2011, Kobayashi et al. 2005a, Kobayashi et al. 2005b).

2 Clinical features of DLSS

2.1 Signalment

Degenerative lumbosacral stenosis has been reported to be a prevalent occurrence in large breed and working dogs, with the German Shepherd being frequently associated with this condition (Danielsson and Sjöström 1999; De Risio et al. 2001, Linn et al. 2003, Gödde and Steffen 2007; Suwankong et al. 2008). The German Shepherd has been extensively studied and appears to present skeletal particularities at the level of the lumbosacral joint, increasing the susceptibility to cauda equina compression, including a reduced vertebral canal height and a high prevalence of degenerative changes compared with controls (Ondreka et al. 2013). Despite DLSS increased prevalence in larger breed dogs it is worth highlighting that smaller agility dogs, such as the Border Collie or the English Cocker Spaniel, have been increasingly found to suffer from this condition (*vide* results). In general, it is considered that working, military or agility dogs are at greater risk of developing DLSS (Linn et al. 2003, Jones et al. 2000). Males have been reported to be more

commonly affected than females, with 6-7 years old being the most typical age of onset (Danielsson and Sjöström 1999, Suwankong et al. 2008).

2.2 Presenting complaints & typical clinical signs

Typically, cases present following a commonly protracted history of suspected lumbar pain, persistent or episodic, made evident in activities where more force is loaded at the lumbosacral joint and its associated lateral foramina (De Risio *et al.* 2000). Reluctance or yelping episodes when standing up, going up stairs or jumping or being protective when touched around the lumbar region should warn the clinician of a potential underlying DLSS. Lameness can be evident in some cases, characterised by a toe-touching or nerve root signature posture (Figure 1:1). More severe cases can present with faecal or urinary incontinence, attributable to involvement of the nerve roots giving rise to the pudendal nerve (S1-S3). The most consistent finding in DLSS dogs is the presence of a painful response on direct palpation of the lumbosacral region or lifting of the tail. In stoic dogs, pressure over the lumbosacral joint can be performed while the pelvic limbs are kept flexed over the examiner's thigh, inducing over-extension of the joint (Sjöström 2003).

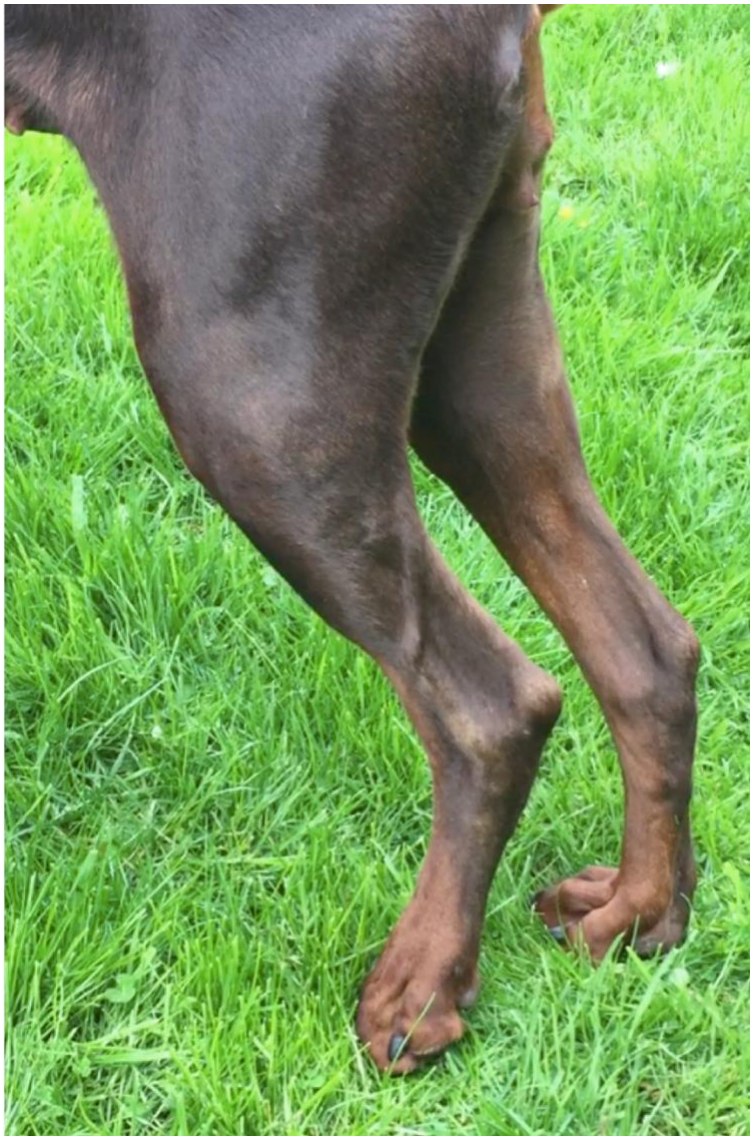

Figure 2.2:1: A Doberman exhibiting a toe touching posture. DLSS cases characterised by nerve entrapment or impingement (foraminal stenosis) can present with a toe-touching or nerve root signature posture, where the effected limb is not fully supported on the ground whilst the animal is standing. This could translate positional root-related pain or possible uncomfortable sensations (pricking, tingling or numbness) when supporting the limb.

2.3 Neurological examination findings

Neurological examination will vary from patient to patient, and neurological deficits might not be evident in every patient. Gait analysis can demonstrate paresis (weakness) or a stiff gait affecting one or both pelvic limbs (Worth et al. 2019). Segmental spinal reflexes may include an absent, reduced or normal withdrawal or flexor reflex, impairment would be related with sciatic nerve dysfunction which arises from the L6-S1 spinal nerves. An intact or exaggerated patellar reflex (L4-L6 nerve roots innervating the femoral nerve) can be sometimes elicited, exaggerated by means of a reduced compliance of the muscles innervated by the sciatic nerve (paradoxical hyperreflexia). Pelvic limb muscle atrophy, also compatible with a sciatic distribution is found frequently. Perineal reflex and anal tone, as well as tail carriage and movement can be altered in some cases (De Risio *et al.* 2000, Worth *et al.* 2019). Ataxia (incoordination) is not a feature of DLSS disease, as the spinal cord is not contained within the vertebral canal at the level of the lumbosacral joint.

The distribution of frequently identified owner presenting complaints, based on data prospectively collected over 3 years at Dovecote Veterinary Hospital is available in Figure 1:2 (data in preparation).

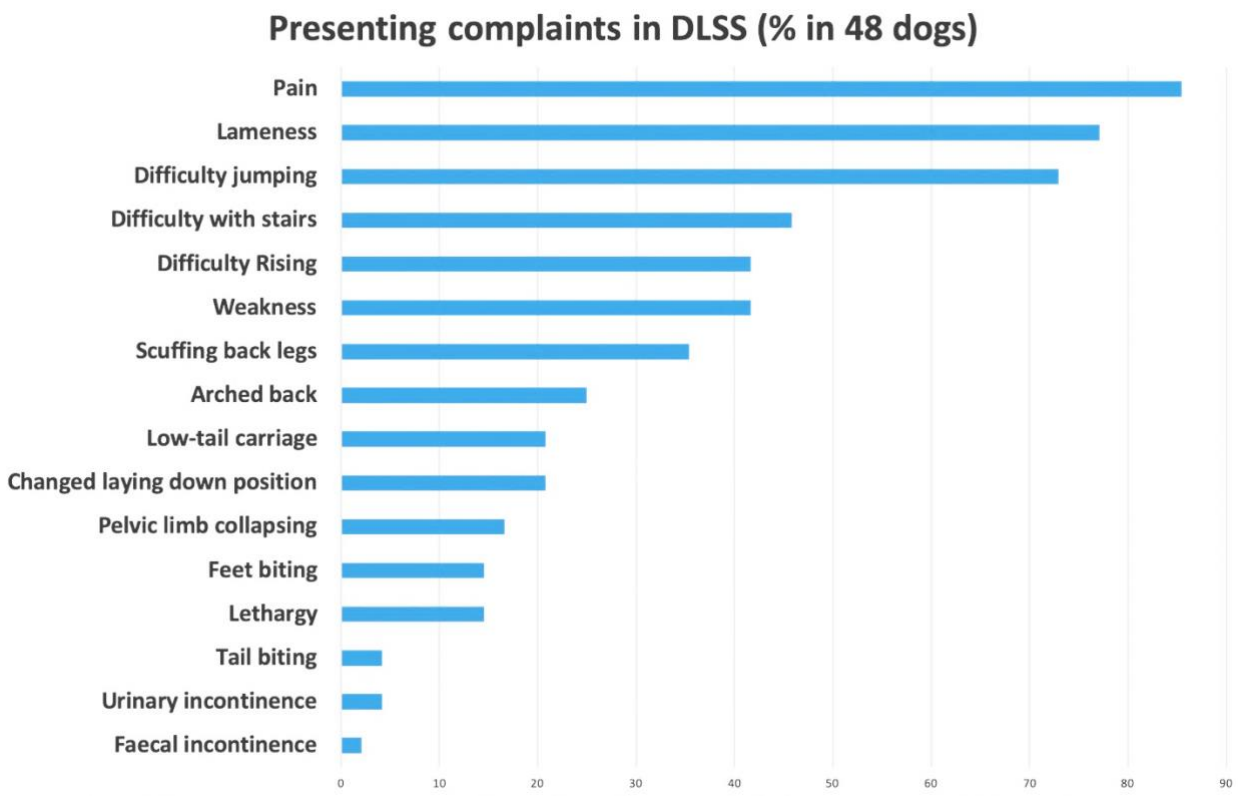

Figure 1:2: Distribution of owner presenting complains of 48 dogs affected with DLSS, diagnosed at Dovecote Veterinary Hospital (2017-2019).

2.4 Differential diagnosis

Clinical signs of DLSS are varied and not pathognomonic for this condition (Figure 1:2). An array of other pathologies, some also typically affecting older and larger dogs, can be found in these cases. A list of differential diagnoses affecting pelvic limb function and leading to lumbar pain are presented in Table 1:2. It is particularly important to consider and possibly rule-out the presence of concomitant orthopaedic conditions, such as hip dysplasia, typically found in the same population prone to DLSS.

3 Diagnosis of DLSS

Degenerative changes at the level of L7-S1 are commonly found in older and particularly active dogs. When imaging an older patient, changes at the level of the lumbosacral joint are almost invariably found (Jones and Inzana 2000). Common examples include spondylosis (readily identifiable on radiographs) and intervertebral disc protrusion (on cross-sectional imaging and contrast studies (Axlund and Hudson 2003). Therefore, it is important to associate typical clinical signs, rule out other concurrent conditions (Table 1:2) and analyse imaging findings in light of this, in order to correctly diagnose DLSS.

3.1 Plain radiography

Radiography has a very important role in first opinion assessment as a quick screening process, which can in some cases help rule out several of the common confounders of this condition (Table 1:2). When performing radiographs in cases suspected of DLSS, it is worth performing both a lateral and a dorsoventral view, including both coxofemoral joints.

The most commonly reported radiological finding in DLSS is lumbosacral spondylosis, which is not pathognomonic of this condition as it is a prevalent incidental finding in older patients or alongside other conditions (e.g. discospondylitis). Other reported findings include evidence of a narrowed intervertebral disc space, subluxation (e.g. sacrum subluxated ventral to L7), osteochondrosis or a vacuum phenomenon (De Risio et al. 2001; Suwankong et al. 2008). Vertebral malformations can also be identifiable through radiography. Even in the presence of changes at the level of the lumbosacral joint level, radiography does not provide enough soft tissue detail in order to be diagnostic of DLSS on its own (De Haan et al.1993).

Differential diagnosis and common confounders
Vascular ▪ Aortic thromboembolism **Inflammatory/infectious** ▪ Discospondylitis ▪ Osteomyelitis ▪ Physitis ▪ Neuritis ▪ Sacroiliitis **Trauma** ▪ Fracture ▪ Subluxation L7-S1 ▪ Tail-pull injury (neuropraxia) **Anomaly** ▪ Tethered cord syndrome ▪ Arachnoid diverticula ▪ Meningeal cysts **Degenerative** ▪ Degenerative myelopathy ▪ Intervertebral disc extrusion ▪ Osteochondrosis ▪ Osteoarthritis / synovial cysts **Neoplasia** ▪ Osteosarcoma ▪ Nerve sheath tumours ▪ Meningioma ▪ Metastatic disease (e.g. prostatic carcinoma) **Orthopaedic conditions** ▪ Hip dysplasia ▪ Cruciate disease ▪ Gracilis myopathy ▪ Osteoarthritis **Anorectal disease** ▪ Anal gland inflammation/infection/neoplasia **Testicular/perineal disease** ▪ Inflammation/infection/neoplasia

Table 1:2: Differential diagnosis and common confounders of DLSS. Adapted from Meij and Bergknut 2010, Sjöström 2003.

3.2 Contrast radiography: myelography, discography and epidurography

Myelography relies on the instillation of a contrast agent in the subarachnoid space of a patient. Considering that the dural sac usually extends over the lumbosacral joint in dogs, vertebral canal compression can potentially be identified. However, the dural sac can terminate before the lumbosacral joint and this technique does not provide information regarding the foraminal component of DLSS, particularly the foramen middle and exit zones (De Risio et al. 2000).

Discography relies on the instillation of a contrast agent within the centre of an intervertebral disc, in DLSS typically L7-S1. It can delineate intervertebral disc protrusions however it fails to detect nerve root involvement of intra-epidural pathology. This can be partially overcome by combining this technique with epidurography (De Risio et al. 2000).

Epidurography relies on the instillation of a contrast agent in the epidural space of a patient. This procedure can be technically less challenigng than myelography, however complete filling of the epidural space might be difficult to achieve and contrast is reabsorbed more quickly. Injection of contrast medium between S3 and Ca1 has been reported to increase diagnostic accuracy for DLSS changes (De Risio et al. 2000).

These techniques have fallen into increasing disuse with the advent and increased availability of cross-sectional imaging, particularly MRI (Worth et al. 2019).

3.3 Computed tomography

Computed tomography (CT) is a cross-sectional imaging technique, providing more detail on both soft and osseous tissue than conventional radiography. Alterations described on CT imaging of dogs with DLSS include the presence of a narrowed intervertebral foramen and vertebral canal, loss of epidural fat, increased soft tissue opacity, bulging of the intervertebral disc margin, and spondylosis (Jones et al.1996). Computed tomography is also particularly useful for the recognition and definition of lumbosacral malformations. However, considering the prevalence of

degenerative changes particularly in older larger dogs (Jones and Inzana 2000), DLSS should be suspected when compatible clinical signs are found in conjunction with increase in soft tissue opacity at the level of the cauda equina or associated nerves in the absence of epidural fat – potentially indicating the presence of an enlarged nerve root or epidural fibrosis – particularly when a narrowed intervertebral foramen or vertebral canal is identified (Jones et al.1996).

3.4 Magnetic resonance imaging

Magnetic resonance imaging (MRI) is superior to CT in identifying soft tissue lesions leading to DLSS (Ramirez and Thrall, 1998) and it is the imaging diagnosis of choice in the diagnosis of DLSS (Mayhew et al. 2002). Evidence of vertebral canal stenosis can be readily identified in most cases as MRI is sensitive in identifying intervertebral disc protrusions or the presence of degenerative joint disease (Meij and Bergknut 2010, Jones et al. 2000). Foraminal stenosis can be assessed on both parasagittal and transverse sections through visualisation of changes indicative of stenosis of the foraminal canal (e.g. bony changes) or the loss of epidural fat (Figure 2:1) (Gödde and Steffen 2007). Evidence of nerve root enlargement can be readily identifiable, particularly in dorsal views (Figure 2:2).

3.5 Other diagnostic modalities

3.5.1 Electrophysiologic studies

Electromyography (EMG) is the electrophysiologic study of muscles, assessing muscular insertional, spontaneous or voluntary electrical activity. EMG has a role differentiating between denervation atrophy and disuse muscle atrophy, aiding in the distinction between motor unit diseases and orthopaedic disease (Cuddon 2002, De Risio et al. 2000). Electromyography has been shown to be altered in some dogs affected by DLSS, particularly when neurological deficits are present (Oliver et al, 1978, Sisson et al.1992). Considering the frequent compromise of the L7 nerves in DLSS, it is reasonable to find these changes in the musculature innervated by the sciatic

nerve and its tibial and common peroneal branches. Nerve conduction studies (NCS) evaluate the electrical conduction of motor or sensory nerves. Specific NCS were shown to have diagnostic value in assessing DLSS dogs, including tibial nerve somatosensory evoked potentials (SEP) and cord dorsum potentials (CDP). The latency of lumbar SEP is prolonged in DLSS affected dogs versus controls (Meji et al. 2006) and CDP onset latency, F-wave onset latency, and F-ratio were increased in dogs with MRI evidence of foraminal stenosis of L7 (Harcourt-Brown et al. 2019).

3.5.2 Epidural steroid injection

Epidural steroid injection (ESI) has been described as treatment of DLSS in a single study (Janssens et al. 2009). In that report it was found that all patients responded to an initial instillation. Extrapolating this finding into the day-to-day clinical setting, where patients will often present with evidence of vertebral canal stenosis but concomitant orthopaedic disease, ESI has a potential as a diagnostic tool in DLSS. Although distinction between DLSS and other conditions should be guided by diagnostic imaging findings, it is the clinical experience within our research group that epidural steroid injections can be helpful in making that distinction clearer (Personal communication Mike Targett).

4 Syndromes within a syndrome

DLSS describes a syndrome and it is an umbrella term for distinct processes leading to compression of the cauda equina and associated nerve roots. An intuitive insight into DLSS is to look for the different components surrounding the cauda equina that include the intervertebral disc, soft tissues, and the bone components of L7 and S1 vertebrae, describing the different degenerative or pathologic processes occurring at these structures. However, regardless of the process causing compression, each has a specific localisation for the compressive process enabling similar treatment modalities.. Therefore, DLSS can be further divided into three broad sub-populations, trying to reach a compromise between the localisation of the compressive lesion and its underlying

aetiology – vertebral or central canal stenosis, foraminal stenosis and cases where a dynamic compression or instability is suspected. The need for this more detailed reclassification has been made evident by recent literature, where DLSS cases with foraminal stenosis have been studied exclusively (Harcourt-Brown et al. 2019). Although these subpopulations have not yet been demonstrated as distinct in terms of signalment or clinical signs, surgical treatment modalities for these subpopulations can indeed be distinct, e.g. a compression located within the vertebral canal might be addressed by a dorsal exploratory and decompressive surgery whilst a unilateral foraminal stenosis might require solely a lateral foraminotomy. Nonetheless, these presentations can overlap such as in cases where a vertebral canal stenosis occurs alongside foraminal stenosis, requiring a combination of different treatment techniques.

4.1 Vertebral or central canal stenosis

In **vertebral or central canal stenosis**, the intervertebral disc, namely L7-S1, is commonly found protruding into the vertebral canal. Also, soft tissue proliferation such as ligamentum flavum thickening or the presence of degenerative joint disease with associated synovial cysts might develop and cause vertebral canal stenosis (Forterre et al. 2006, Schmökel et al. 2016). Osteochondrosis is another reported process that can cause cauda equina compression at this level (Hanna 2001). The L7 nerves do not course directly above the intervertebral disc, travelling along the vertebral canal over a lateral recess (Figure 1:3), so should not be affected in a pure vertebral canal stenosis. Despite the presence of different processes causing compression at this level, surgical management of this cases will almost invariably require a dorsal approach by means of a dorsal laminectomy, which is described in detail later in the manuscript.

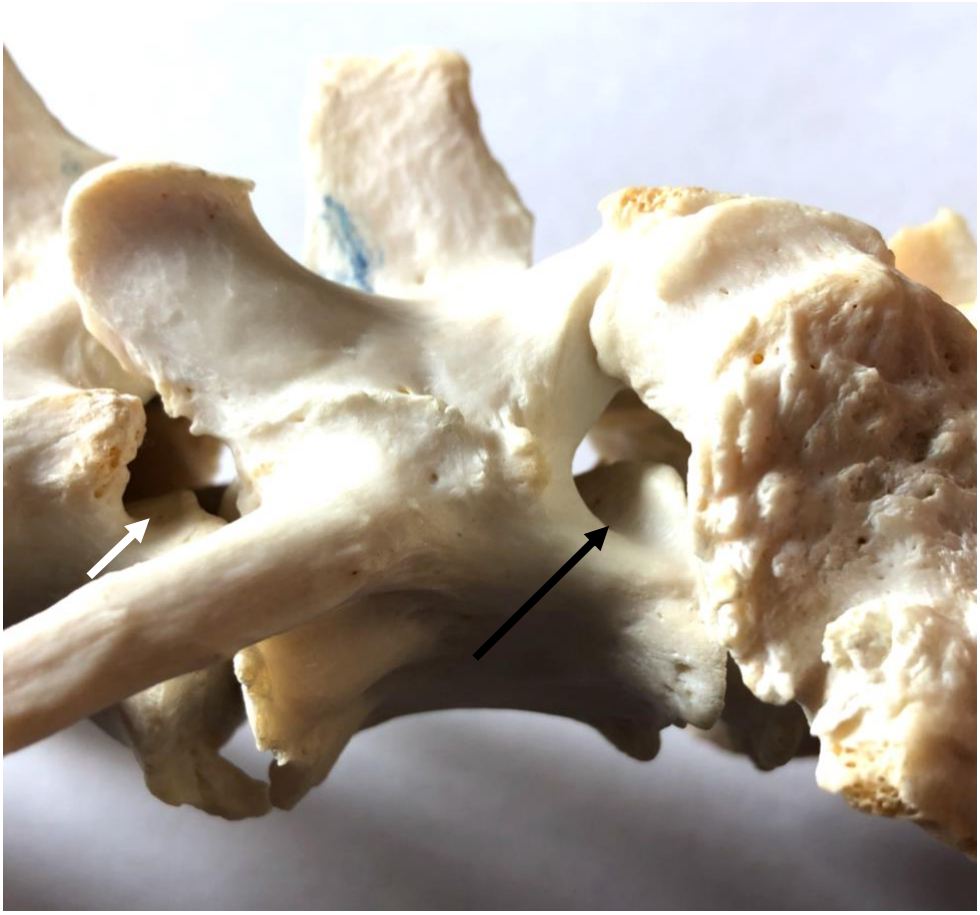

Figure 1:3: Lateral recess (indicated by arrows) are the osseous tubular passageway where the L6 (white arrow, less pronounced) and L7 (black arrow, more pronounced) nerves run before leaving the vertebral canal. The lateral recess forms the entrance zone of the lateral foramen continuing into the middle and exit zones.

4.2 Foraminal stenosis (uni or bilateral)

An intervertebral foramen, also termed lateral foramen, is formed by two consecutive vertebrae. In DLSS the lateral foramina of interest are the ones between L7 and S1. These can be divided into an entrance, middle and exit zone (Figure 1:4) (Gödde and Steffen 2007), and the intervertebral foramina run just cranial to the L7-S1 intervertebral disc.

Foraminal stenosis can result in impingement or entrapment of a nerve root, through a static stenosis of the foramen or relating to a dynamic change in its volume. Reported causes of foraminal stenosis and L7 nerve root compression include the presence of osteophytes at the middle and exit zones, soft tissue proliferation, lateralised disc protrusions at the level of the middle and exit zones and malformation of the articular facets (Gödde and Steffen 2007).

Higher availability of cross-section imaging in veterinary practices have increased awareness of the prevalence and significance of foraminal stenosis in the aetiology of pain and neurological dysfunction of a large proportion of dogs affected with DLSS (Gödde and Steffen 2007, Worth et al. 2018, Steffen 2018, Harcourt-Brown et al. 2019). Foraminal involvement is a frequent finding in DLSS patients, being reported in 68-84% of cases (Mayhew et al. 2002, Rapp et al. 2017).

Compression of the nerve root associated with impaired perfusion can lead to endoneurial oedema (Yoshizawa et al. 1995) eventually leading to irreversible nerve root enlargement (Lindahl 1951). Different surgical techniques have been reported in managing this DLSS subpopulation, namely lateral foraminotomy or distraction techniques, described in detail later in the manuscript.

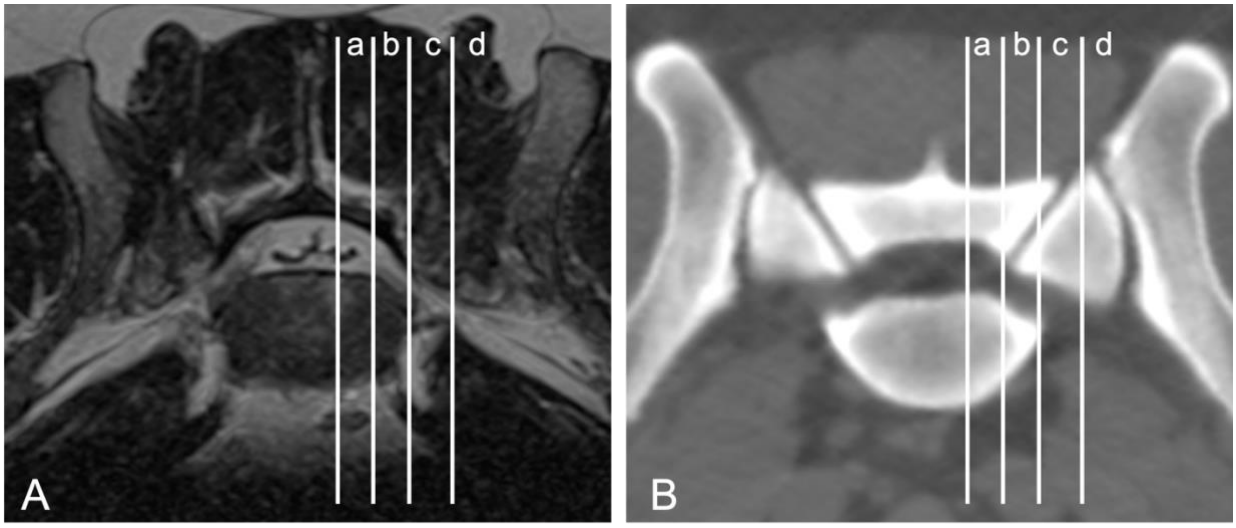

Figure 1:4: T2-weighted transverse MRI image (A) and CT transverse section (B) with a bone algorithm at the level of the L7-S1 intervertebral disc, demonstrating foraminal zones: (a) entrance zone , (b) middle zone, (c) exit zone. The extraforaminal zone is represented by the letter (d). Based on Gödde and Steffen 2007.

4.3 Lumbosacral dynamic compression & suspected instability

The L7-S1 has been reported as the most mobile segment within the lumbar vertebral column in clinically normal dogs (Jones *et al*. 2008). Dynamic compression can be possible, despite difficult to prove, even in the absence of compressive lesions on static images (Jeffery et al. 2014). This appears to be particularly evident in foraminal stenosis, which can be static and readily identifiable on MRI, or suspected when the L7 nerve roots are found enlarged in the absence of a clear foraminal stenosis on cross-sectional imaging. Dynamic foraminal area variation has been shown to occur in flexion and extension, being found to be smaller when the vertebral column is extended instead of flexed (Jones *et al*. 2008, Worth *et al*. 2017).

Lumbosacral instability has been suspected, from the initial descriptions of DLSS to be present on a proportion of these patients (Indrieri 1988, Meij et al. 2007). Its contributing role to DLSS is controversial in the literature (Jeffery et al. 2014). The presence of lumbosacral misalignment with evidence of subluxation between L7 and S1, identified as dorsal or typically ventral subluxation of the sacrum relative to L7, has been suspected to be an indication of lumbosacral instability (Meij et al. 2007, Golini et al. 2014). Despite this, radiological studies have shown no difference between the degree of subluxation of the sacrum between DLSS affected and non-affected German Shepperd dogs (Schmid and Lang 1993).

Nonetheless, stabilisation techniques can play a role particularly in the presence of advanced degeneration and protrusion of the L7-S1 intervertebral disc, presence of a severe ventral or dorsal displacement of S1 in respect to L7 or in non-strictly DLSS pathologies such as subluxation/trauma or discospondylitis (Sharp and Wheeler 2005).

4.4 Congenital vertebral malformations

Congenital vertebral malformations can be found throughout the vertebral column including the level of the lumbosacral joint. Several vertebral malformations can occur at this later level including hemivertebrae, spina bifida and lumbosacral transitional vertebra (LTV).

A transitional vertebra is a congenital abnormally occurring between vertebral sections, where a vertebra is misshaped and misformed. Lumbosacral transitional vertebra is a congenital abnormality occurring between the last normally-formed lumbar vertebrae and normally-formed sacral vertebra, presenting morphological characteristics of both a lumbar and a sacral vertebra (Damur-Djuric et al. 2006). Despite LTV being extremely variable in their presentation, frequently its classification is based on the morphology of the transverse processes (Figure 1:5). LTV can occur in any breed, however an increased prevalence was described in both the German Shepperd dog and the Greater Swiss Mountain (Damur-Djuric et al. 2006).

The presence of lumbosacral vertebral abnormalities can be an incidental finding not necessary causative of pathology (Bertram et al. 2019), however the presence of LTV was found to be a predisposing factor for DLSS (Flückiger et al. 2006). Compression of the cauda equina and associated nerve roots can occur at the level of the vertebral canal, the intervertebral foramina or be extra-foraminal. The variability of LTV alongside compression of the neural structures at different levels, makes standardized treatment for this presentation impractical, sometimes requiring innovative approaches when considering surgery. It is therefore considered a particular case where central canal, lateral canal and suspected instability can be present at varying degrees.

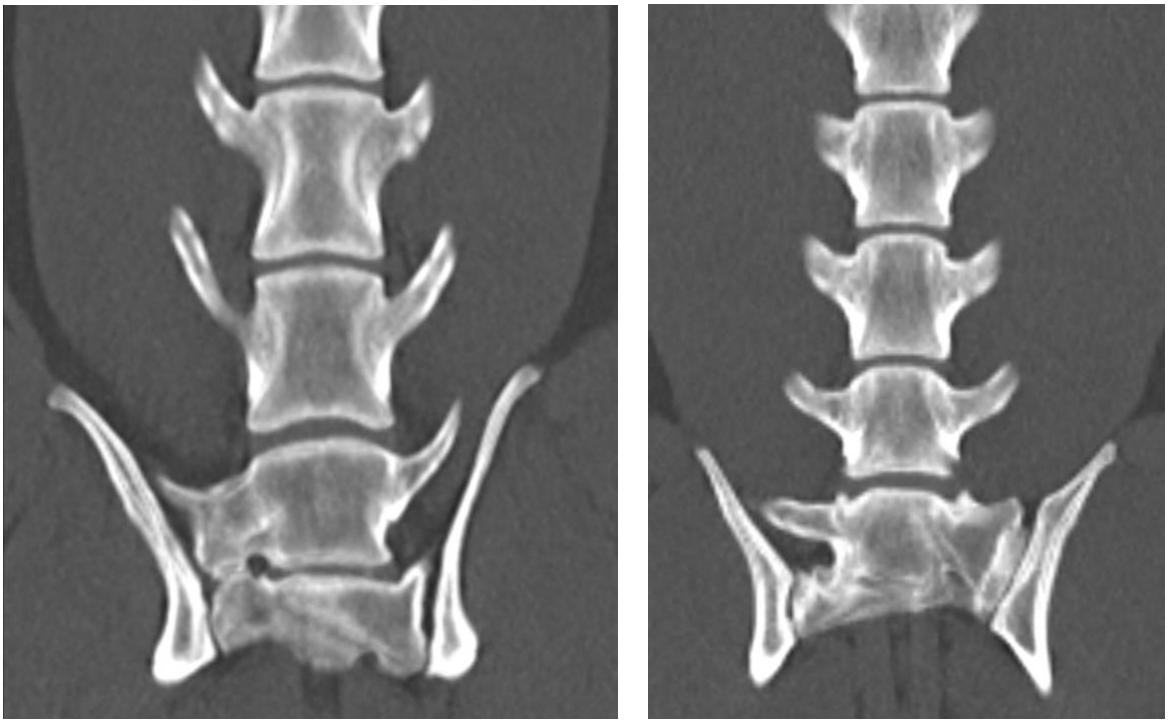

Figure 1:5: Computed tomography in the dorsal plane using a soft tissue algorithm centered at the level of the lumbosacral joint in two dogs. Both CT images demonstrate sacralization of L7, characterized by malformation of a transverse process, with abnormal fusion with the ilium wings.

4.5 Other non-DLSS compressive conditions

Other well-recognised conditions can affect the lumbosacral joint and could theoretically be considered as part of the DLSS complex, such as intervertebral disc extrusions (IVDE) or discospondylitis. However, these are considered to be a separate clinical condition, still arising from degenerative (IVDE) or infectious (discospondylitis) processes but with well described imaging features and treatment modalities distinct from the ones of DLSS (Burkert et al. 2005, Aikawa et al. 2012, Gomes et al. 2016).

5 Treatment options for DLSS

5.1 Conservative management

Conservative management is usually the first line treatment in dogs suspected to suffer from DLSS at the level of the primary care veterinarian. There are no standardised protocols described for conservative management of DLSS in the literature. Management is based on oral analgesics and anti-inflammatory drugs, typically through non-steroid anti-inflammatories, gabapentin or tramadol (Jeffery et al. 2014, De Decker et al. 2014). Restricted exercise is usually applied for 4-6 weeks and physiotherapy is sometimes advised. It is possible that many mild non-diagnosed DLSS cases are successfully managed in first opinion practice (Jeffery et al. 2014), therefore it seems reasonable that conservative management be initially attempted before referral.

5.2 Epidural-steroid injection

Epidural steroid injection, is a frequent procedure in the treatment of lower back pain in people (McLain et al. 2005, Parr et al. 2009). In animals it has been experimentally tested in a rat model of lumbar radiculopathy leading to relief of clinical signs, and it was studied in a population of healthy Beagles where it was related to only minimal complications (Hayashi et al. 1998, Liotta et

al. 2016).

Epidural-steroid injection in dogs has been described in a single study, through the the translaminar instillation of methylprednisolone acetate in the epidural space over the L7-S1 intervertebral disc in a population of 38 dogs (Janssens et al. 2009). In that report, following the first instillation all patients were reported to have initially improved, with 18.4% receiving a single-instillation, and long-term clinical improvement reported in 79% of cases following more than one instillation. Specific details on outcome of the subpopulation receiving a single-instillation are not described or are difficult to infer, and it is questionable if a single epidural can be utilised successfully as treatment in DLSS affected dogs. That same study also demonstrated that ESI would have a temporary effect, requiring several repeated procedures to reach a more extended effect (Janssens et al. 2009).

Epidural steroid injection is generally considered a safe procedure in dogs (Janssens et al. 2009, Liotta et al. 2016, Salmelin et al. 2019), however severe complications secondary to an epidural injection have been reported in a dog (Remedios et al. 1996). Its theoretical advantages over oral medication include a more targeted therapy, being applied in the immediate vicinity of the affected nerve roots leading to lesser systemic effects and higher local dosages (McLain et al. 2005). These advantages allied with a rapid response to treatment, gives epidural steroid injection the potential of being utilised as a single treatment, a diagnostic test or even as predictor of subsequent surgical management outcome of DLSS.

Although this has not yet been stablished in veterinary medicine, the terminology “epidural steroid injection” is utilised in human medicine describing this procedure (Buttermann 2004, McLain et al. 2005, Wilkinson and Cohen 2013,) and therefore it is the terminology adhered to throughout this thesis.

The mechanism of action of epidural steroid injections is still not well understood and it is most likely multifactorial. Corticosteroids can directly or indirectly inhibit the synthesis or release of pro-inflammatory mediators, alter neuromuscular junction and neuron conductivity namely nociceptive C-fiber conduction, as well as reduce oedema formation secondary to increased capillary damage and permeability (McLain et al. 2005). Further to this, the direct instillation of an aqueous substance in the epidural space can lead to osmotic dilution and removal of inflammatory mediators (Wilkinson and Cohen 2013). ESI advantages over oral medication include a more targeted corticosteroid delivery with a reduction of systemic effects (McLain et al. 2005). It must be noticed and highlighted that despite the utilisation of a potent anti-inflammatory over the affected region, inflammation appears to be a rare finding in cases of foraminal stenosis and secondary nerve root enlargement (Matiasek et al. 2008). ESI is a less-invasive procedure with considerably less costs than surgery. However, the need of repeated instillations can lead to aggravated costs and reduce owner compliance (Janssens et al. 2009). ESI is a frequent procedure in the treatment of lower back pain in people despite its mechanism of action still remaining unexplained (McLain et al. 2005, Parr et al. 2009).

Since Janssens et al. 2009 study, ESI has not been investigated further by other research groups in DLSS affected patients.

5.3 Surgical management

Surgical management of DLSS has been extensively reported. Surgical techniques applied to DLSS are either based on stabilisation of the articular components to reduce dynamic pathology (Slocum and Devine 1986, Méheust 2000, Hankin et al. 2012, Smolders et al. 2012, Golini et al. 2014), or decompression of neural structures (Danielsson and Sjöström 1999, Jones et al. 2000, De Risio et al. 2001, Linn et al. 2003, Janssens et al. 2000, Suwankong et al. 2008, Rapp et al. 2017). Surgical management has been reported to lead to higher rates of clinical improvement

(67% to 97% rates) in comparison with other treatment modalities (Danielsson and Sjöström 1999, Janssens et al. 2000, Jones et al. 2000, De Risio et al. 2001, Linn et al. 2003, Gödde and Steffen 2007, Suwankong et al. 2008, Hankin et al. 2012, Smolders et al. 2012, Golini et al. 2014). Decompression surgical techniques are the most extensively reported and currently utilised approaches in surgically managing DLSS patients.

5.3.1 Dorsal laminectomy

Traditionally surgical decompression in DLSS cases, has based itself in the utilisation of dorsal vertebral canal decompression via dorsal laminectomy with or without concurrent discectomy (Jeffery et al. 2014). This approach has the advantages of removing dorsal components leading to vertebral canal stenosis, namely ligamentum flavum hypertrophy or synovial cysts as well as providing an extremely good overview of the region overlying the L7-S1 intervertebral disc, allowing the removal of static compressive lesions to the cauda equina such as osteochondrosis or intervertebral disc protrusions.

The lateral limits of this approach are the articular processes themselves, which should be preserved, and the lamina axial to this level (Figure 1:6). The articular facets should be preserved in order to avoid secondary fractures (Moens and Runyon 2002). The cranio-caudal extension of the approach is variable from a more conservative approach where just extirpation of the ligamentum flavum and partial dorsal laminectomy of the first sacral segment is performed (Kinzel et al. 2004, Gödde and Steffen 2007), to more extensive laminectomy until non-affected neural structures are exposed (Sjöström 2003). Despite the frequent finding of intervertebral disc protrusions in DLSS, discectomy (the incision of the annulus fibrosus and its partial removal from underneath the cauda equina) may not be strictly necessary for long-term surgical success (Suwankong et al. 2008, Worth et al. 2019).

Figure 1:6: Dorsal view of the lumbosacral joint (A), revealing the dorsal laminectomy approach with preservation of the articular facets. Lateral view of the lumbosacral joint (B1, B2) comparing the size of intervertebral foramen in a non-operated dog (B1) and following lateral foraminotomy (B2).

5.3.2 Lateral foraminotomy

Foraminal stenosis presents challenges that cannot be overcome by a dorsal laminectomy alone. Traditionally decompression of the intervertebral foramina has been performed alongside L7-S1 dorsal laminectomy, through both dorsal and medial approaches, by means of extending the laminectomy (Danielsson and Sjöström 1999, Jones et al. 2000, De Risio et al. 2001, Linn et al. 2003, Suwankong et al. 2008). However, extension of the laminectomy results in limited access to lateralised foraminal compressions, increased risk of articular facet fractures, and increased instability of the lumbosacral joint (Moens and Runyon 2002, Gödde and Steffen 2007, Jeffery et al. 2014, Rapp et al. 2017). Alternative surgical approaches to the L7-S1 intervertebral foramina have been reported. Endoscopy-assisted foraminotomy was performed through a dorsal mini-laminectomy (Wood et al. 2004) in clinically normal dogs and a cadaver study tested the feasibility of a transiliac approach to the foramen (Carozzo et al. 2008).

In 2007, Gödde and Steffen described a lateral approach to foraminotomy that could be performed bilaterally as a stand-alone procedure or in combination with a partial dorsal laminectomy of L7-S1. This is based on the direct access to the lateral foramina of L7-S1, which is enlarged cranially by the high-speed burring of the dorsal aspect of the transverse process of L6 to the base of the cranial articular process of L7 (Figure 1:6). Gödde and Steffen reported 20 dogs, with only mild intra-operative complications and subsequent clinical improvement in 95% of cases with no recurrence of clinical signs, however no long-term follow up studies have been reported. Foraminotomy from within the vertebral canal has been reported, however dorsal laminectomy provides only limited access to lateralised foraminal compressions, as well as no access to middle, exit or extra-foraminal zone compression.

Since its initial development, lateral foraminotomy has now been reported by different groups, that appear to confirm this technique as a safe and effective procedure, leading to marked improvement

of clinical signs in cases where DLSS is characterised by foraminal stenosis (Gödde and Steffen 2007, Togni et al. 2014, Worth et al. 2018).

5.3.3 Stabilisation and distraction techniques

Several stabilisation techniques have been reported in dogs suffering from DLSS. These were based on the non-rigid L7-S1 transarticular fixation with bilateral implant placement (pins or positional screws) alone or in conjunction with dorsal decompression (Slocum and Devine, 1986, Bagley 2003, Hankin el al. 2012, Golini et al. 2014), rigid fixation and fusion based on pedicle screws fixed with a bone cement bridge (Sharp and Wheeler 2005) and pedicle screw-rod fixation (Méheust 2000, Meij et al. 2007, Smolders et al. 2012).

The principle behind stabilisation procedures is the reduction or elimination of any dynamic compression of the neural structures in the lumbosacral joint as well as potential reduction of degenerative changes that could develop due to instability. Distraction has also the potential of enlarging the intervertebral foramina, which can be beneficial in cases of foraminal stenosis. However, all of these procedures carry possible postoperative risks of complications due to implant failure (Smolders et al. 2012, Golini et al. 2014).

6 Preparatory work

Before commencing this thesis, knowledge and particularly long-term outcome information regarding decompressive surgery addressing foraminal stenosis was limited.

Also, upon initiating this study, alternative treatments to surgery in canine degenerative lumbosacral stenosis (DLSS) remained limited and reliable predictors of outcome are lacking.

An alternative non-surgical method has been described in a single retrospective study, through the infiltration of methylprednisolone acetate in the epidural space over the L7-S1 intervertebral disc in a population of 38 dogs (Janssens et al. 2009). In that report, all dogs were reported to improve following the first ESI with 18.4% receiving a single-instillation, and long-term clinical improvement reported in 79% of dogs following more than one ESI. Specific details on outcome of the subpopulation receiving a single-instillation are not described or are difficult to infer, and it is questionable if a single ESI can be applied successfully as treatment in DLSS affected dogs. The study also demonstrated that ESI had a temporary effect, requiring several repeated procedures to achieve a more prolonged effect (Janssens et al. 2009). The same study based DLSS diagnosis on epidurography or discography with no advanced imaging being performed. No further articles have investigated ESI efficacy in canine DLSS.

In order to address this lack of information in the literature, two different studies, a retrospective study and a prospective study were formulated, in order to investigate some of these questions.

7 Aims of the Thesis

The aims of the present study are the following:

- Review retrospectively the short and long-term outcome in a cohort of canine patients who underwent lateral foraminotomy in the treatment of lumbosacral foraminal stenosis.
- Assess the usefulness of a single ESI in the management of DLSS and evaluate ESI as a predictor of outcome following decompressive surgery.
- Compare the outcomes of ESI and decompressive surgery.

A set of hypotheses were proposed:

- Lateral foraminotomy is a safe and useful treatment in cases of lumbosacral foraminal stenosis.
- ESI can be effective in DLSS cases, leading to transient alleviation of clinical signs.
- ESI can be a reliable predictor of surgical outcome, e.g. a positive response to ESI can indicate a positive response to surgical decompression.
- Surgical decompression can lead to a more favourable outcome than a single ESI

Chapter II

MATERIALS & METHODS

1. Retrospective study: Long-term outcome following lateral foraminotomy as treatment for DLSS in dogs

1.1. Animals

Medical records of dogs undergoing lateral lumbosacral foraminotomy presented to the neurology service at Dovecote Veterinary Hospital between May 2012 and January 2017 were reviewed. Cases were included when presented with clinical signs compatible with a lumbosacral neurolocalisation, when MRI evidence of foraminal stenosis was found, and unilateral or bilateral foraminotomy was performed either alone or in combination with midline dorsal laminectomy. Dogs were excluded if there was evidence of a concomitant relevant orthopaedic, neoplastic or inflammatory disease. Further to this, all cases in which a herniated disc extrusion was identified were excluded, as this is a clinically distinct pathology from DLSS.

Signalment and clinical information on presentation was recorded, including any previous treatment for DLSS. Dogs were classified as pet dogs or working dogs, a category which included agility dogs. Clinical signs consistent with a lumbosacral neurolocalisation consisted of lumbosacral pain, reluctance to climb stairs, jump or rise from sitting, lameness, and neurologic deficits (i.e. reduced flexor withdrawal, proprioceptive deficits, nerve root signature/toe touching, tail paresis, absent perineal reflex, urinary incontinence).

Dogs were further classified into pre-surgical groups according to severity of clinical and neurological signs (Table 2:1) using a modified scoring system (Danielsson and Sjöström 1999, Gödde and Steffen 2007). The nomenclature “lateral foraminotomy” was used throughout this study, referring to the lateral foraminotomy approach and technique described elsewhere (Gödde and Steffen 2007).

Classification of Dogs According to Severity of Clinical and Neurological Signs
Group 1 (mild) Lumbosacral pain Reluctance to climb stairs, jump or raise up Lameness Muscle atrophy No neurologic deficits
Group 2 (moderate) Lumbosacral pain Reluctance to climb stairs, jump or raise up Lameness Muscle atrophy Moderate neurologic deficits (e.g. reduced flexor withdrawal, proprioceptive deficits, nerve root signature/toe touching)
Group 3 (severe) Lumbosacral pain Reluctance to climb stairs, jump or raise up Lameness Muscle atrophy Severe neurologic deficits (e.g. tail paresis, absent perineal reflex)

Table 2:1: Classification of dogs according to severity of clinical and neurological signs. Adapted from De Risio et al. 2001 and Gödde and Steffen 2007.

1.2 Advanced Imaging

All dogs underwent MRI under general anaesthesia using a low field 0.25 Tesla (T) permanent magnet (Esaote VetMR Grande, Genova, Italy). MRI was performed in dogs in lateral recumbency in a neutral position, using a dedicated Dual Phased Array spinal coil. Imaging studies included a minimum of T2-weighted (T2W) sagittal and transverse images and dorsal short tau inversion recovery (STIR) images. MRI scans were assessed by board-certified neurologists (ML, MT). Foraminal stenosis was determined when either one or both of the following imaging changes was found: (1) complete loss of fat signal or only a minimal rim of fat signal left in the foraminal zone in parasagittal or transverse T2W images (Gödde and Steffen 2007) (Figure 2:1), (2) presence of a compressive asymmetric intervertebral disc protrusion on transverse T2W images at the level of the intervertebral foramina. The presence of an ipsilateral hyperintense L7 nerve root on transverse T2W images and dorsal STIR (Figure 2:2) supported a diagnosis of foraminal stenosis, although this was not used as a definitive criterion. Vertebral canal stenosis was defined by the presence of over 25% of lumbosacral vertebral canal attenuation on midsagittal images (Jones et al. 2000, Gödde and Steffen 2007). Pre-operative presence of nerve swelling was recorded. Subsequent lumbosacral MRI studies were retrieved when available, and compared with pre-operative MRI studies. Comparison focused on assessment of subjective evidence of recurrence of foraminal stenosis and nerve root swelling. Foraminal stenosis and nerve root swelling were evaluated as described above. Duration of clinical signs in these cases was also reported.

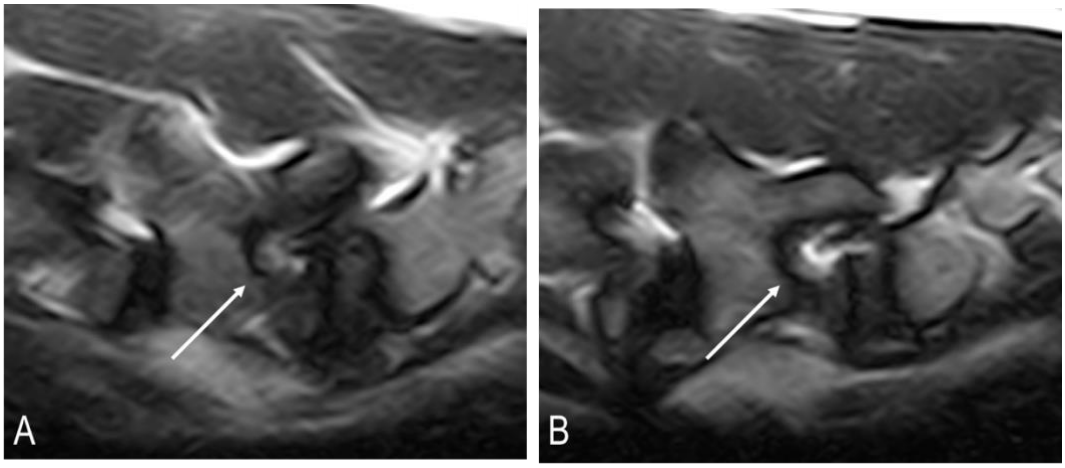

Figure 2:1: T2W parasagittal images of a dog with right unilateral foraminal stenosis. White arrows indicate the intervertebral foramina. An almost complete fat signal loss is noticeable in the affected foramen (A). Foraminal stenosis can be observed more clearly when affected (A) and non-affected (B) foramina are compared.

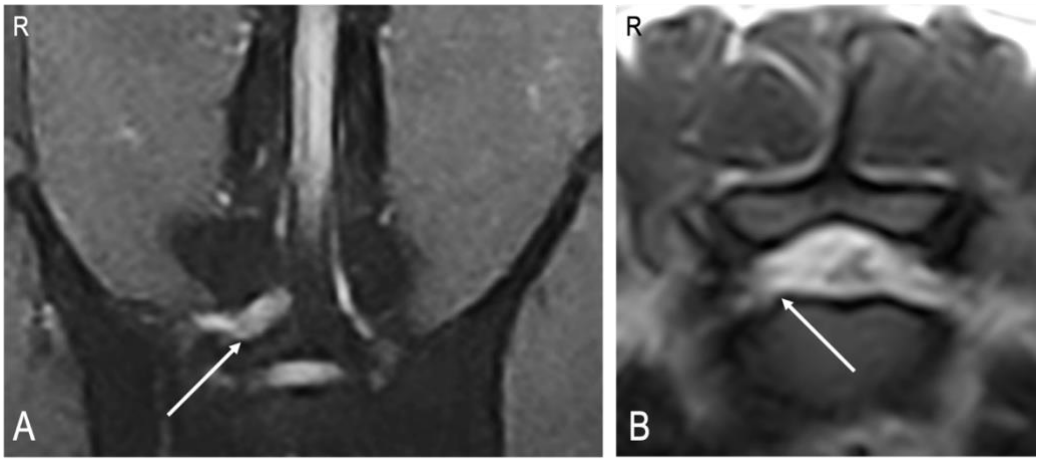

Figure 2:2. T2W transverse (A) and dorsal STIR (B) images of a dog with right unilateral foraminal stenosis. Subjective L7 nerve swelling on the affected site can be observed on both images, indicated by white arrows. Hyperintensity obtained on dorsal STIR (B) is notable when compared to contralateral unaffected foramen.

1.3 Surgical procedures

Evidence of foraminal stenosis at the level of the lumbosacral junction on MRI was seen as an indication for a lateral foraminotomy (unilateral or bilateral). Vertebral canal stenosis on MRI was an indication for performing a concurrent dorsal laminectomy. Surgical procedures were performed by two different board-certified neurologists. Information on intra and post-operative surgical complications was retrieved. Following surgery, dogs were discharged with instructions of cage rest for 4 to 6 weeks, rehabilitation and concurrent pain-relief as required. Dogs would then be allowed to gradually resume regular exercise and routine.

1.4 Outcome and recurrence

Short-term outcome was acquired from postoperative consultations with a board-certified neurologist performed at 6 weeks and within the initial 6 months following surgery. Following this period of time, long-term outcome was obtained through telephone interviews with the owners or, in cases of relapse, subsequent consultation data was utilised.

Outcome was considered (1) excellent if complete resolution of clinical signs was present at follow-up consultations or the owner considered the dog to be clinically normal (2) good if there was substantial but incomplete improvement in clinical signs or the owner considered the dog to have some recurrent episodes of pain or lameness (3) poor if the dog did not improve after surgery or deteriorated further (De Risio et al. 2001, Gödde and Steffen 2007).

Recurrence of clinical signs attributable to DLSS was determined and information on initial neurological classification, interval from surgery to recurrence and outcome post-recurrence was retrieved. Treatment post-recurrence was divided into three: repeate surgery, unrelated surgery and non-surgical. Repeat surgery included cases where there was re-intervention at the previously operated site. Unrelated surgery included cases where a new surgery at an unrelated surgical site

was performed. Non-surgical included cases where there was no additional surgical intervention.. Further details on specific cases were reported when considered relevant to the scope of the study.

2. Prospective study: Single dose epidural steroid as a treatment and predictor of outcome following subsequent decompressive surgery in DLSS with foraminal stenosis

2.1 Study design

Ethical approval for the study was granted by The School of Veterinary Medicine and Science at the University of Nottingham (Approval number: 2711 190,326; Approval date: 10 May 2019). Written informed consent was obtained from owners of all dogs prior to enrolment. Dogs presented to the neurology service at a single referral hospital between February 2017 and May 2019, with clinical signs compatible with DLSS were prospectively recruited.

Inclusion criteria were (1) clinical confirmation of DLSS through compatible clinical signs, (2) MRI evidence of intervertebral foraminal stenosis with identification of L7 nerve root enlargement and/or lumbosacral vertebral canal stenosis (Gödde and Steffen 2007). Dogs presenting with concomitant relevant orthopaedic, neoplastic, inflammatory, developmental conditions or evidence of L7-S1 intervertebral disc extrusion were excluded.

Owners of dogs that potentially met the inclusion criteria were informed of the clinical trial at time of admission, and offered an initial ESI at time of diagnosis. Decompressive surgery was offered to patients when ESI was unsuccessful or following relapse of clinical signs. Procedures and time frames are detailed below.

Owner questionnaires were devised enquiring about the presence of typical clinical features of DLSS. Inferred pain, mobility and quality of life were assessed through a numerical 0 (poor) to 10 (good) whole number scale; in inferred pain, 0 corresponded to no pain and 10 to extreme pain. Three questionnaires were devised and provided to the owners at three different time-points: at initial consultation (Supplement 1), 2 to 4 weeks following ESI (Supplement 2), and 6-8 weeks following surgical management (Supplement 3). Initially, pilot questionnaires were developed to

create an assessment tool for owner-inferred prognosis. These addressed possible predisposing factors such as exercise levels and dog function. The information regarding clinical signs was based on previous DLSS literature (De Risio et al., 2001; Gödde and Steffen, 2007; Jeffery et al., 2014), as well as previous personal experience in managing the condition and data collected during the first retrospective study. This pilot questionnaire was performed in 3 cases diagnosed with DLSS, before a final version of the questionnaire was developed. For the owner-inferred outcome measures, initially a visual analogue scale was to be utilised, however during this trial period, it was clear that owner engagement was superior when a number scale was used. For the more descriptive information on clinical signs, both "changed laying down position" and "feet biting" options were added to the final questionnaires, based on owner description in these 3 pilot questionnaires.

Signalment, weight, duration of clinical signs, previous treatments attempted, clinical and neurological findings were recorded. Dogs were initially classified into clinical severity groups through the use of a mild, moderate and severe grading scoring system (**Table 2:1**). Dogs were classified as pet dogs or working dogs, the latter category including agility dogs, and daily exercise length was classified as above or below an hour.

2.2 Diagnosis and epidural steroid injection

Following clinical and MRI diagnosis of DLSS, each patient underwent an ESI under general anaesthesia. General anaesthesia protocol was standardised for all patients. Instillation of methylprednisolone acetate (Depo-Medrone 40 mg/ml, Pfizer) was performed into the lumbosacral epidural space in accordance with a previously reported dosage protocol, of 1 mg/kg with a minimal volume of 0.5 ml (Janssens et al. 2009). In order to confirm the correct placement

of the needle, a neurostimulation technique was performed following a previously validated method, with the animal in sternal decubitus (Garcia-Pereira et al. 2010). A disposable spinal needle electrode (Natus TECA MyoJect, 50 mm length, 25 gauge) was placed and muscle twitching of the tail at a stimulus intensity up to 0.30 mA was required before local instillation (Garcia-Pereira et al. 2010). Epidural steroid injections were performed by the authors. Following ESI, all dogs were discharged with instructions for restricted exercise and continuation of their current oral treatment protocol in order to avoid interference with ESI, except when managed with non-steroidal anti-inflammatory drugs which were stopped. The owners were handed the first questionnaire at initial consultation (Supplement 1). A follow-up consultation was performed between 2 to 4 weeks later, in accordance with previously reported median length of ESI effect of 11 days (4–14 days) (Janssens et al. 2009). A second questionnaire was handed to the owners at that time (Supplement 2). Information was obtained from owners regarding complications, particularly focusing on signs of systemic absorption of corticosteroids such as polyphagia, polydipsia and polydipsia (Behrend and Kemppainen, 1997, Salmelin et al. 2019). The length of time until clinical response was observed through an open question in the second questionnaire.

2.3 Surgical decompression

Surgical decompression was offered to patients following a minimum period of two weeks following ESI, when unsuccessful or after relapse of clinical signs. Lateral foraminotomy (unilateral or bilateral) was performed when there was evidence of foraminal stenosis at the level of the lumbosacral junction, with a concurrent dorsal laminectomy when there was evidence of midline vertebral canal stenosis (Gödde and Steffen 2007). Concurrent L7-S1 discectomy was not performed. Surgical procedures were performed by two board-certified neurologists. Following surgery, dogs were discharged with instructions of cage rest for 4 to 6 weeks, rehabilitation and concurrent pain-relief as required. Dogs would then be allowed to gradually resume regular

exercise and routine. Follow-up consultations were performed between 6 to 8 weeks following surgery and a third questionnaire was given to the owners (Supplement 2).

2.4 Outcome

Outcome was divided into (1) clinical outcome, as assessed by a board-certified neurologist on follow-up consultations, (2) owner inferred outcome based on pain, mobility and quality of life scores obtained through questionnaires.

Clinical outcome to both ESI and surgical decompression was considered (1) complete if clinical signs had resolved at follow-up consultations (2) incomplete if there was substantial but incomplete improvement in clinical signs (3) failed if the dog did not improve or deteriorated further. Relapse was assessed following initial response to ESI or surgical decompression, being defined as deterioration of clinical signs following an initial improvement. Time from ESI to relapse was obtained at the time of completion of the second questionnaire or, if occurring later, through telephone interviews with the owners. Follow-up time was collected for dogs without relapse through telephone interviews with the owners at the time of completion of this study.

In patients undergoing both ESI and surgical decompression, comparison of clinical and owner inferred outcome was performed.

2.5 Statistical analysis

The owner-inferred outcome variables (pain, mobility and quality of life) were compared between groups: (1) pre-epidural vs. post-epidural, (2) pre-epidural and post-surgical questionnaires. Data were analysed using statistical software (Minitab 18 Statistical Software19, NY). The outcome variables were screened at the univariable level using Student's *t*-test or Mann–Whitney *U* test, dependent upon the normality of the distribution of the data, which was determined via visual

inspection of histograms. P values ≤0.05 were considered significant in all analyses.

Chapter III

RESULTS

1. Retrospective study

1.1 Signalment and history

45 dogs were identified which had undergone lateral foraminotomy. Breed distribution was German Shepherd Dog (n=8), Border Collie (7), Crossbreed (6), Cocker Spaniel (5), Dalmatian (4), Labrador Retriever (3), Boxer (3), Rottweiler (2), German Short-Haired Pointer (2), Belgian Malinois, Gordon Setter, Golden Retriever, Lurcher and Weimaraner (1 for each). 27 males and 18 females were identified with a mean age of 74.71 months (median 76, 34 - 156). Mean duration of clinical signs before surgery was of 6.88 months (median 6; 0.75 - 30). The severity group allocation of cases before surgery was: mild (n=26), moderate (n=16) or severe (n=3) (Table 2:1). Eleven (24.4%) were working or agility dogs.

1.2 Pre-operative treatments

Three dogs had previously undergone dorsal laminectomy with concurrent unilateral extension at 16, 17 and 60 months prior to lateral foraminotomy. Long term response to surgery was considered inadequate and lateral foraminotomy was performed ipsilaterally in all 3 cases. One further dog had received an epidural steroid injection with a transient 2 weeks' improvement in clinical signs, whilst the remaining 41 dogs (91.1%) had previously shown inadequate response to systemic conservative therapy with rest and analgesia.

1.3 Surgical procedures and complications

Unilateral lateral foraminotomy was performed in 11 dogs (24.4%), alone in 7 dogs and in combination with dorsal laminectomy in 4 dogs. Bilateral lateral foraminotomy was performed in 34 dogs (75.6%), alone in 8 dogs and with concurrent dorsal laminectomy in 26 dogs. None of the

dogs underwent concurrent lumbosacral discectomy. Mild haemorrhage from abnormal vascular supply to the articular facet joint was reported as an intraoperative complication in 1 case.. Postoperative complications were present in 12 dogs and included subcutaneous seroma in 7 dogs (15.6%), suspected wound infection responsive to broad-spectrum antibiotic course in 2 dogs and increased pain within the first 4 weeks in 3 dogs. Suspected wound infection was not confirmed with culture and sensitivity tests. All of these complications were resolved within 4 weeks following surgery.

1.4 Short-term outcome

Short-term outcome information was available for all patients and was considered good in 5 cases (11.1%) and excellent in the remaining 40 cases (88.9%).

1.5 Long-term outcome

Long-term outcome was available in 34 cases (75.5%) with a mean follow-up time of 22.9 months (median 18; 8-54). Poor long-term neurological outcome was reported in one 10-year-old male German Shepherd Dog which having initially responded well to lateral foraminotomy, subsequently developed progressive ataxia and paraparesis. Based on the clinical presentation, age, breed and normal spinal MRI findings a presumptive diagnosis of degenerative myelopathy (DM) was suspected. All 33 remaining cases were reported by the owner to have an excellent long-term outcome.

Recurrence of clinical signs was identified in 5 dogs (11.1%) and occurred in a mean of 10 months after surgery (median 8; 4-22). Initial neurological classification of these cases was mild (n=2), moderate (2) and severe (1), and all had a repeat MRI scan performed at a mean of 11.8 months following foraminotomy (median 9, 8-22). One of these dogs was the German Shepherd suspected

to have developed DM. Re-establishment of foraminal compression at the surgical site was not demonstrated in any of the remaining 4 dogs (Figure 3:1). Nerve root swelling which had been identified on pre-surgical MRI, was also present in subsequent imaging of 4 cases (Figure 3:1). When nerve root swelling was not present on pre-surgical MRI this was also not identified on subsequent imaging (1 case).

Treatment following recurrence was non-surgical in four cases and one case that on cross-sectional imaging had developed a contralateral foraminal stenosis underwent lateral foraminotomy of the newly affected site. Non-surgical treatment was conservative (3) or epidural steroid-injection (1). All five cases improved following treatment and their long-term outcome was considered excellent at a mean of 26.3 months' post-recurrence (median 27; 8-43).

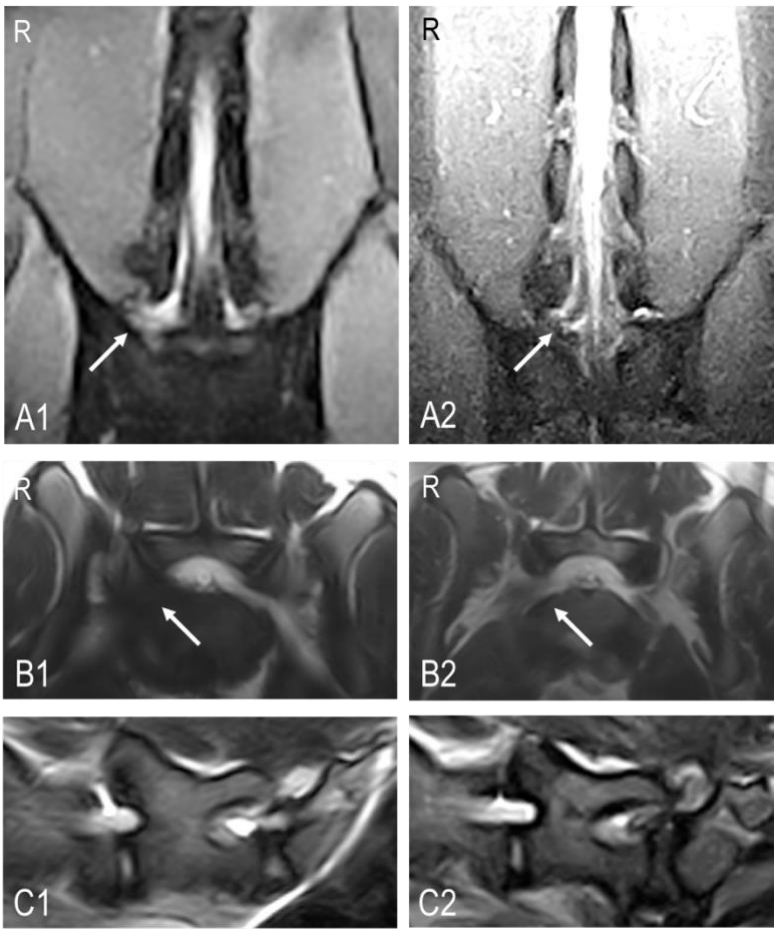

Figure 3:1. Pre-operative dorsal STIR (A1), T2W transverse (B1), T2W parasagittal (C1) and 22 months postoperative dorsal STIR (A2), T2W transverse (B2), T2W parasagittal (C2) of a dog with right unilateral foraminal stenosis. Right nerve root swelling is noticeably decreased 22 months following surgery (white arrows); however, it is still subjectively enlarged when compared with the contralateral nerve root. Right foraminal stenosis (white arrow) is clearly noticeable previously to surgery (B1) being resolved following surgery (B2). Lateral foraminotomy post-surgical borders are clearly identified (C2) with no evidence of reestablishment of stenosis. This patient underwent a right-sided lateral foraminotomy, with recurrence of clinical signs 22 months following surgery. Right foraminal stenosis was not proven to be re-established and following conservative management, complete resolution of clinical signs was achieved.

2. Prospective study

A total of 88 dogs were assessed for enrolment for a suspected diagnosis of DLSS. Thirty-eight dogs were excluded for presenting a non-DLSS diagnosis, details are described in Figure 3:2. Of the remaining 50 dogs, 41 dogs underwent ESI with nine dogs receiving an alternative treatment modality at the owner's request. Following ESI, nine dogs did not return for a follow-up consult failing to complete the second questionnaire. Thirty-two dogs were re-examined and completed the questionnaire following ESI. All dogs had undergone unsuccessful medical management through non-standardised medication protocols and restricted exercise before presentation.

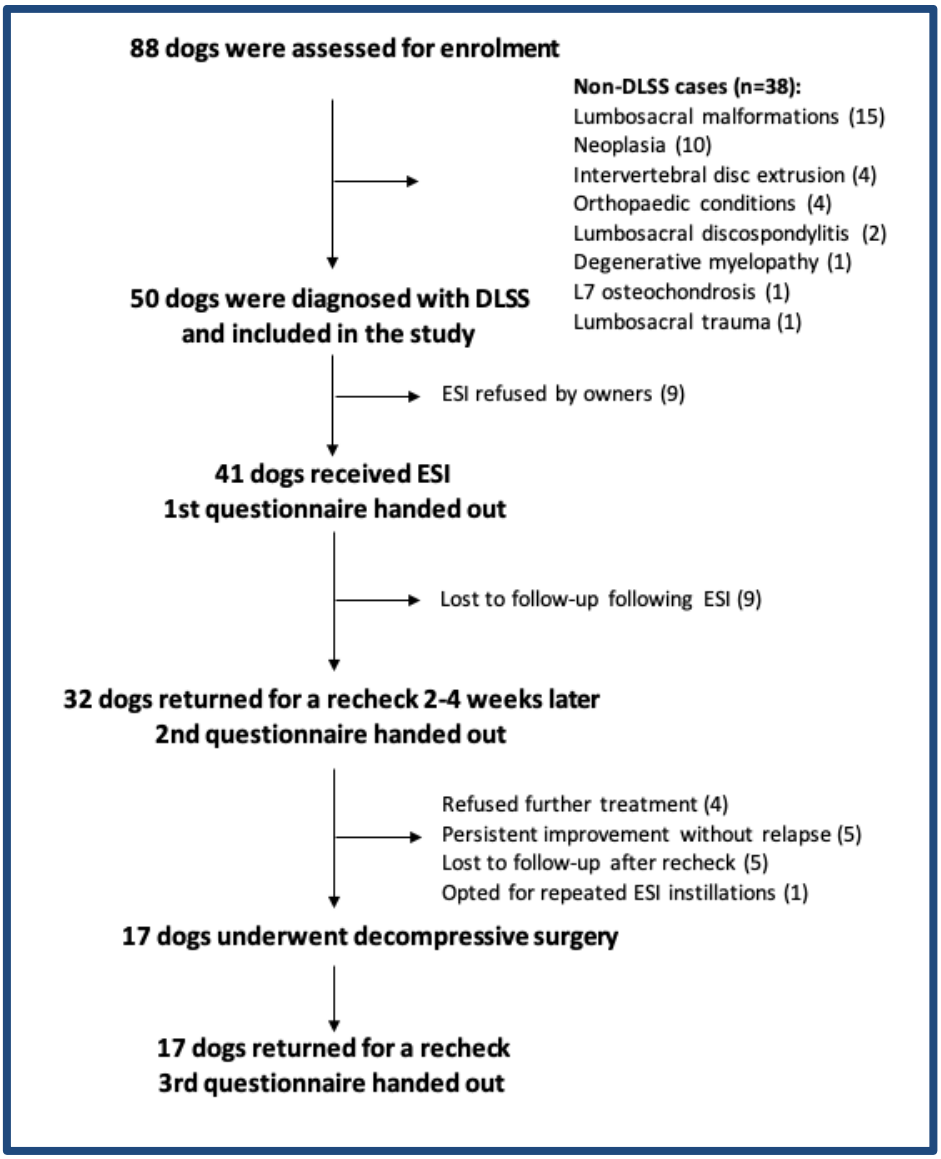

Figure 3:2. Diagram depicting the clinical trial sequence, included patients and reasons for exclusion (prospective study).

2.1 Animals

Breed distribution was Labrador Retriever (n=6), Border Collie (4), Crossbreed (4), German Shepherd Dog (3), Golden Retriever (2), Airedale Terrier, Beagle, Belgian Shepherd Dog, Boxer, Chinese Shar-pei, Cocker Spaniel, Dalmatian, German Pointer, Rhodesian Ridgeback, Rottweiler, Siberian Husky, Springer Spaniel, Staffordshire Bull Terrier (1 for each). Seventeen males and fifteen females were identified with a mean age of 75.1 months (median 70.5; 15-150). Mean duration of clinical signs before diagnosis was of 4.7 months (median 4; 0.3-12) and mean weight was of 27.4 kg (median 27.1; 6.8-42.6). A total of five dogs were working or agility dogs (15.6%), with seventeen (53.1%) being exercised for over 1 hour daily.

2.2 Outcome and statistical analysis

Clinical outcome is detailed in Table 2:2. Thirty-two patients were assessed following ESI. Initial grading score was mild in 14 (43.8%), moderate in 15 (46.9%) and severe in three (9.4%) dogs.

An improvement after ESI was seen in 27/32 dogs (84.4%) with partial response in 14 dogs and a complete response in 13 dogs. In 5 dogs (15.6%) no clinical response to ESI was evident. All five dogs where no clinical response was identifiable had subsequent surgical decompression. Of the 14 dogs in which a partial response was seen, 9 relapsed with 7 having surgical decompression, one opting to have ESI repeated and one being refused further treatment by their owners; the remaining 5 were lost to long term follow-up. Of the 13 dogs with a complete response to ESI, 8 relapsed with 5 subsequently having surgical decompression and 3 being refused further treatment by their owners; the remaining 5 had persistent improvement without relapse. Information on relapse post-ESI was available in 22 dogs and occurred in 17 (77.2%), at a mean of 2.4 months (median 2; 0.5-6). The five dogs with a persistent improvement without relapse following ESI had a last-contact mean follow-up time of 9.4 months (median 8; 2-21).

Time length until clinical response following ESI was only detailed by the owners of 17 dogs and was a mean of 12.9 days (median 14; 2-28). No complications were identified from ESI and a single dog presented transient clinical signs compatible with systemic absorption of corticosteroids.

A total of 17 dogs underwent decompressive surgery (Figure 3:2). Initial grading score was mild in 6, and moderate in 11 dogs. Bilateral lateral foraminotomy was performed as a standalone procedure in 4 dogs and with concurrent dorsal laminectomy in 13 dogs. Post-surgical improvement was identified in all 17 dogs, with a complete response seen in eight dogs and a partial response in nine dogs. No intraoperative complications were identified. In the five dogs where ESI failed to show improvement, all five improved post-surgically with partial response in 2 dogs and a complete response in 3 dogs (Table 2:2).

The results of owner inferred outcome are described in Table 2:3 and depicted in box and whisker plots Figure 3:3 and Figure 3:4. The analysed score values were found not to be normally distributed and the Mann Whitney test was used for comparison between groups.

In the whole population receiving an ESI, there was a statistically significant difference between the pre-epidural and post-epidural outcomes towards reduced pain (pre-epidural median of 5 and post-epidural median of 3, P=0.000), increased mobility (pre-epidural median of 6 and post-epidural median of 8, P=0.002), and greater quality of life score (pre-epidural median of 6 and post-epidural median of 8.5, P=0.003) (Figure 3:3).

A statistically significant difference was also found comparing the post-epidural and post-surgical outcomes, towards reduced pain (post-epidural median of 4 and post-surgery median of 0, P= 0.006, increased mobility (post-epidural median of 8 and post-surgery median of 9, P=0.007), and

greater quality of life score (post-epidural median of 8 and post-surgery median of 9, P=0.024). This difference in scores following surgical decompression, was noticeable particularly in term of pain scores (Figure 3:4). An extreme post-surgical outlier of the quality of life marker (0 mark) was that of a 5-year-old beagle which underwent bilateral foraminotomy combined with dorsal laminectomy (dog 15). This beagle achieved increased mobility and reduced pain, however, was assessed by the owner as having a significant reduction in quality of life due to the development of urinary and faecal incontinence following surgery.

	Initial grading		Clinical response to epidural steroid injection	Relapse			Surgery performed	Clinical response to surgical decompression
	Severity	Numerical		Yes/ No	Time to relapse (months)	Follow-up time (months)		
Case 1	Moderate	12	Partial	Yes	3	NA	BF + DL	Partial
Case 2	Mild	13	Partial	Yes	0.5	NA	BF + DL	Complete
Case 3	Mild	17	Complete	Yes	3	NA	No: owner refused	NA
Case 4	Mild	17	Partial	Yes	1	NA	BF + DL	Partial
Case 5	Moderate	10	Partial	Yes	3	NA	BF	Complete
Case 6	Moderate	10	Complete	Yes	3	NA	No: owner refused	NA
Case 7	Mild	18	Complete	Yes	3	NA	BF + DL	Complete
Case 8	Mild	15	Complete	No	NA	21	No: persistent improvement	NA
Case 9	Moderate	11	Failed	Yes	0.75	NA	BF + DL	Partial
Case 10	Mild	17	Partial	Yes	6	NA	No: repeat ESI	NA
Case 11	Moderate	13	Failed	Yes	2	NA	BF + DL	Complete
Case 12	Mild	16	Partial	Yes	2	NA	BF + DL	Complete
Case 13	Moderate	13	Complete	Yes	0.75	NA	BF + DL	Partial
Case 14	Moderate	11	Complete	Yes	2	NA	BF + DL	Complete
Case 15	Mild	15	Failed	Yes	0.75	NA	BF + DL	Complete
Case 16	Moderate	12	Partial	Yes	0.5	NA	No: owner refused	NA
Case 17	Mild	15	Complete	No	NA	13	No: persistent improvement	NA
Case 18	Moderate	15	Failed	Yes	2	NA	BF + DL	Complete
Case 19	Moderate	15	Partial	Yes	2	NA	BF + DL	Complete
Case 20	Moderate	14	Partial	Yes	0.75	NA	BF	Partial
Case 21	Moderate	14	Partial	Yes	5	NA	BF	Partial
Case 22	Mild	16	Partial	Lost	NA	NA	Lost	NA
Case 23	Severe	7	Partial	Lost	NA	NA	Lost	NA
Case 24	Severe	12	Complete	Yes	2	NA	No: owner refused	NA
Case 25	Moderate	15	Partial	Yes	2	NA	BF	Partial
Case 26	Severe	13	Complete	No	NA	3	No: persistent improvement	NA
Case 27	Mild	16	Failed	Yes	0.5	NA	BF + DL	Partial
Case 28	Moderate	15	Complete	No	NA	2	No: persistent improvement	NA
Case 29	Mild	14	Complete	No	NA	8	No: persistent improvement	NA
Case 30	Mild	17	Partial	Lost	NA	NA	Lost	NA
Case 31	Moderate	12	Partial	Lost	NA	NA	Lost	NA
Case 32	Mild	17	Partial	Lost	NA	NA	Lost	NA

BF, Bilateral foraminotomy; DL, Dorsal laminectomy; ESI, Epidural steroid injection; Lost, Lost to follow-up after recheck following epidural steroid injection; NA, Not applicable.

Table 2:2: Detailed clinical outcome (prospective study).

	General population (n = 32)		Surgically managed (n = 17)		
	Initial grade mean (median, minimum-maximum)	Post-epidural mean (median, minimum-maximum)	Initial grade mean (median, minimum-maximum)	Post-epidural mean (median, minimum-maximum)	Post-surgical mean (median, minimum-maximum)
Pain (0 no pain – 10 extreme pain)	5.4 (5; 2–10)	2.9 (3; 0–6)	5 (5; 2–8)	3.4 (4; 0–6)	1.3 (0; 0–5)
Mobility (0 poor – 10 good)	6.2 (6; 2–10)	7.8 (8; 3–10)	6.5 (7; 3–10)	7.5 (8; 5–10)	9.1 (9; 7–10)
Quality of life (0 poor – 10 good)	6.2 (6; 0–10)	7.8 (8.5; 2–10)	6.5 (6; 3–9)	7.2 (8; 2–10)	8.6 (9; 0–10)

Table 2:3: Detailed owner perceived outcome for dogs having both ESI and decompressive surgery (prospective study).

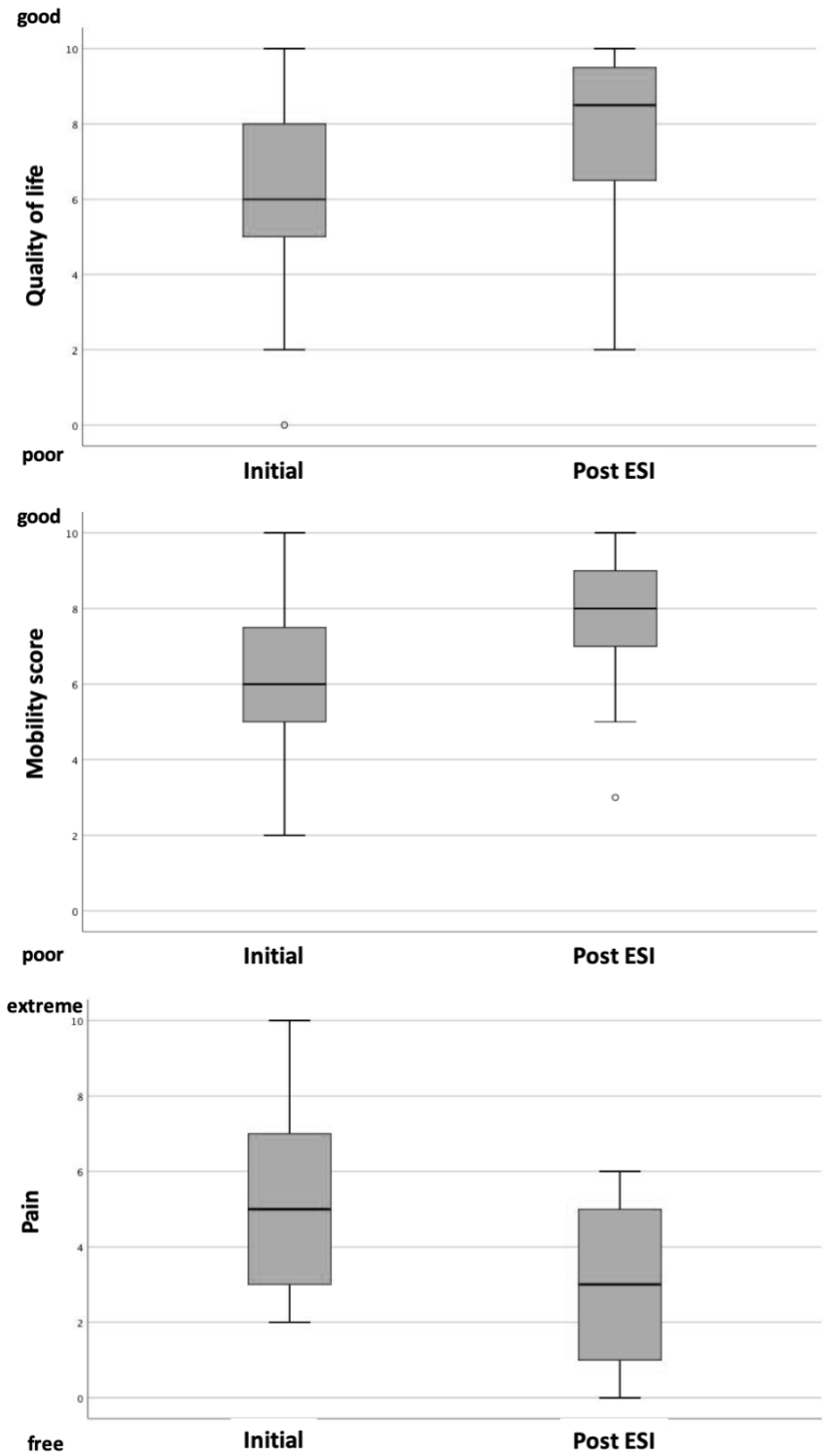

Figure 3:3. Box and whiskers plots representing owner perceived pain, mobility and quality of life scores of the whole population (n = 32) at two time points, initial and following epidural steroid injection (ESI). These were statistically significantly different between groups. Circles beyond the whiskers indicate outliers, with asterisks identifying extreme outliers (prospective study).

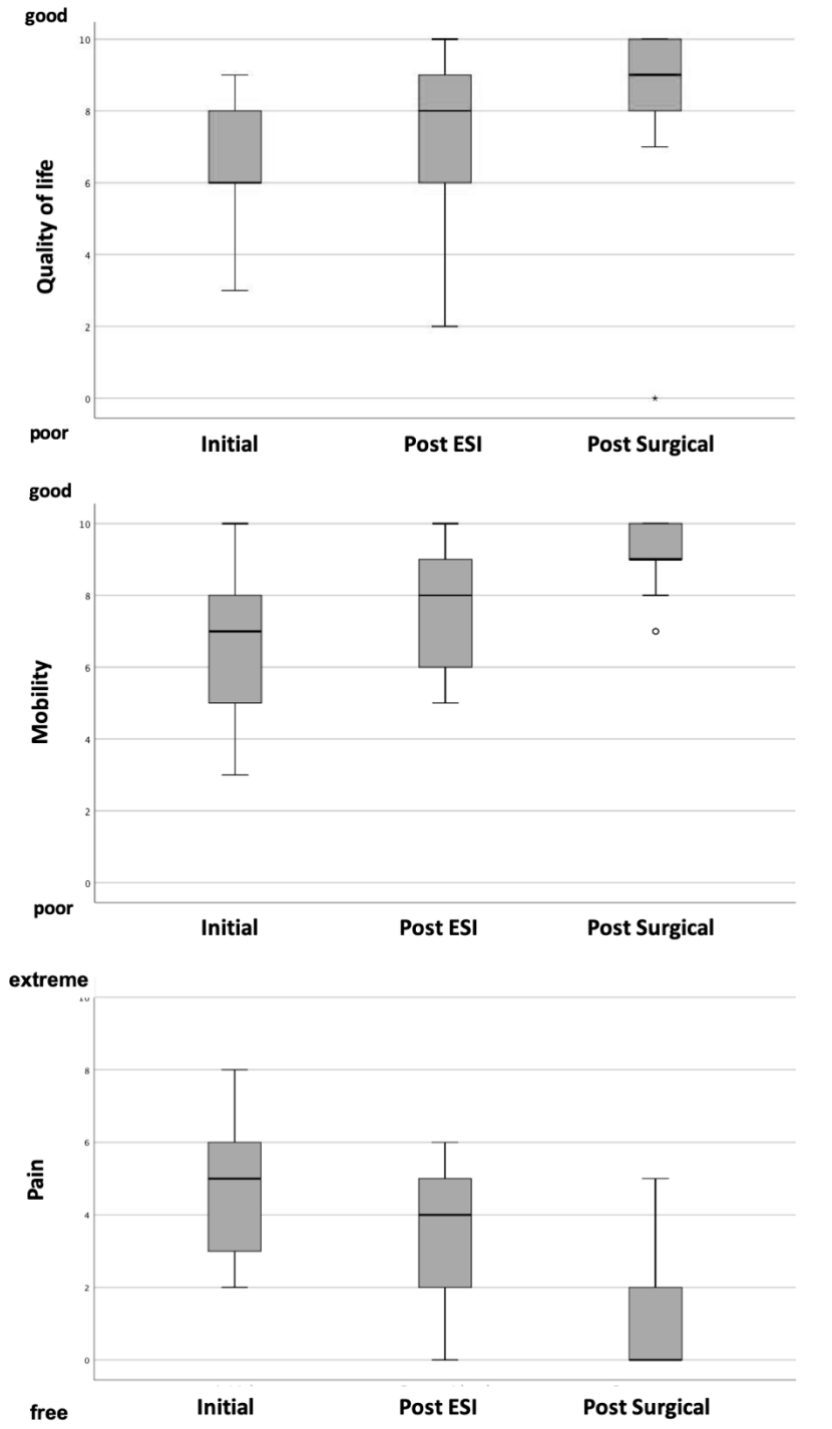

Figure 3:4. Box and whiskers plots representing owner perceived pain, mobility and quality of life scores of the dogs receiving surgery (n = 17) at three time points, initial, following epidural steroid injection (ESI), and following surgery decompression. These were statistically significantly different between groups. Circles beyond the whiskers indicate outliers, with asterisks identifying extreme outliers (prospective study).

Chapter IV

DISCUSSION

1. Retrospective study

The short-term clinical outcome in this cohort of patients was consistent with the findings of Gödde and Steffen in 2007 and is maintained long-term despite some episodes of recurrence. In previous studies reporting dorsal laminectomy decompression, a lack of improvement or worsening of clinical signs is reported to occur in about 15-30% of cases (Danielsson and Sjöström 1999, Janssens et al. 2000, Jones et al. 2000, De Risio et al. 2001, Linn et al. 2003, Suwankong et al. 2008, Rapp et al. 2017) with reports of failed surgery requiring re-intervention (Danielsson and Sjöström 1999, De Risio et al. 2001, Moens and Runyon 2002). The improved results from lateral foraminotomy in this study and studies reporting presence of foraminal stenosis in 68-84% of DLSS cases (Mayhew et al. 2002, Rapp et al. 2017) would suggest that foraminal stenosis with subsequent L7 nerve root pathology represents a significant pathology in DLSS that requires consideration when selecting surgical therapeutic options. Since lateral foraminotomy can address stenosis in the middle and/or exit foraminal zones as well as extra-foraminal stenosis (Gödde and Steffen 2007, Carozzo et al. 2008) it would appear that this more lateral pathology is significant in a proportion of cases. Unrecognised or untreated foraminal stenosis is an important cause of "failed back surgery syndrome", well reported in human medicine (Fritsch et al. 1996, Maher and Henderson 1999).

It has been postulated that failure in the majority of cases following decompression is related with an increased risk of articular facet fractures, instability and inappropriate foraminal stenosis decompression (Moens and Runyon 2002, Gödde and Steffen 2007, Jeffery et al. 2014, Rapp et al. 2017). Lateral foraminotomy has been increasingly performed since it was first described a decade ago (Gödde and Steffen 2007) and allows for effective decompression of the neuroforamen. Besides the clearer and more direct access it provides, this surgery also offers the advantage that

it can be used in combination with dorsal laminectomy without increasing instability. It is worth comparison with alternative techniques involving stabilisation that by reducing mobility and creating distraction at the L7-S1 articulation may work by a similar mechanism to effectively enlarge the foramina and reduce ongoing concussive insult to the L7 nerve within the foramina (Slocum and Devine 1986, Méheust 2000, Hankin et al. 2012, Smolders et al. 2012, Golini et al. 2014). Stabilisation procedures carry post-operative risks of complication due to implant failure (Hankin et al. 2012, Smolders et al. 2012, Golini et al. 2014).

Similar to previous reports the German Shepherd was the most affected breed in this study (Ness 1994, Danielsson and Sjöström 1999, De Risio et al. 2001, Gödde and Steffen 2007, Suwankong et al. 2008). Interestingly Cocker Spaniels, a breed reported to present with caudal lumbar disc herniation (Cardy et al. 2016), represented 8.8% of this population while being sparsely represented in previous DLSS reports (Slocum and Devine 1986, Danielsson and Sjöström 1999, Janssens et al. 2000, Méheust 2000, De Risio et al. 2001, Linn et al. 2003, Suwankong et al. 2008, Hankin et al. 2012, Smolders et al. 2012, Golini et al. 2014, Rapp et al. 2017).

The majority of cases in this study underwent surgery following unsuccessful conservative treatment (91.1%). Interestingly three cases had previously undergone dorsal laminectomy. In these three cases foraminal stenosis had been identified at the time of diagnosis and the dorsal laminectomy had been extended unilaterally, in an attempt to relieve the foramina. Dorsal laminectomy of these cases was performed at a time prior to lateral foraminotomy being offered in this institution. A further case presented with a transient response to epidural-steroid injection with recurrence. Since all of these cases had an excellent outcome following foraminotomy alone this supports the hypothesis that the clinical signs were due to neuroforaminal entrapment rather than vertebral canal stenosis.

In this population, both short- and long-term improvement of clinical signs were identified, with a long-term complete resolution of clinical signs in 97.1% of cases. This percentage is the highest reported in surgical management of DLSS (Danielsson and Sjöström 1999, Janssens et al. 2000, Jones et al. 2000, De Risio et al. 2001, Linn et al. 2003, Gödde and Steffen 2007, Suwankong et al. 2008, Hankin et al. 2012, Smolders et al. 2012, Golini et al. 2014) which is in accordance to previously reported excellent results of this technique (Gödde and Steffen 2007). Being a retrospective study, long-term follow-up was based mainly on telephonic interviews with owners, which can have biased the results. However, the fact that a single case presented a poor outcome which was deemed unrelated to DLSS, reinforce the significance of these results, at least in comparison with previously reported stand-alone dorsal laminectomy outcomes.

Recurrence of clinical signs following surgical therapy for DLSS has been reported for dorsal decompression via a dorsal laminectomy requiring further surgical intervention (Danielsson and Sjöström 1999, De Risio et al. 2001, Moens and Runyon 2002), but has not been previously reported following lateral foraminotomy (Gödde and Steffen 2007). Recurrence in the current study was not shown to be related to reestablishment of foraminal stenosis of the previously operated site on MRI and most cases were managed successfully with non-surgical measures. In the case where a second surgery was required this was at the contralateral foramen which had not been previously surgically decompressed. Evidence of contralateral foraminal stenosis was not present on the initial MRI study. A contralateral foraminotomy resolved the clinical signs suggesting this was the result of progression of DLSS rather than surgical failure or failure to identify foraminal stenosis on initial MRI.

New bone formation following foraminotomy has been reported previously (Wood et al. 2004) and this in conjunction with fibrous tissue generation could lead to a renewed foraminal stenosis with compression of the nerve root (Gödde and Steffen 2007). Subsequent advanced imaging in five dogs, performed at least 8 months following surgery, revealed that the foraminal enlargement that had been achieved by foraminotomy was maintained and that there was no evident spondylosis producing progressive stenosis. However, a larger cohort study with post-operative imaging would be required to confirm this.

The persistence of nerve enlargement identified in 4/5 dogs supports experimental studies documenting chronic irreversible nerve root swelling following entrapment in dogs (Yoshizawa et al. 1995). Compression of the nerve root results in impaired venous and lymphatic drainage resulting in endoneurial oedema (Yoshizawa et al. 1995). Interstitial and perivascular fibrosis then ensues contributing to irreversible nerve root enlargement (Lindahl and Rexed 1951). Despite persistent hypertrophy of the nerve root on MRI, the long-term outcome in all cases post-operatively was considered excellent.

A number of limitations exist in this retrospective current study. Data was collected retrospectively and therefore the population and procedures were not-standardised. However, a set of standardised procedures was adhered to in terms of medical note taking, advanced imaging, surgical management, hospitalisation and subsequent treatment making the data less prone to recall bias. Further to this, short-term follow-up information relied on the expertise of the same people that performed surgery potentiating clinician bias and long-term follow-up was based upon telephone interviews which are both subjective and prone to a caregiver placebo effect. The follow-up period is also variable and a much longer-term follow-up in all cases may have altered our outcome.

The MRI studies used for diagnosis were low-field and some authors may suggest that greater information could be achieved using high-field MRI. However, in human degenerative lumbar disease excellent agreement was found between high and low-field magnets, when comparing vertebral canal stenosis, lateral recess and exit foraminal stenosis as well as good agreement when assessing for spinal nerve compression (Lee et al. 2015).

2. Prospective study

This is the first study that prospectively assesses treatment of a dog population clinically affected by DLSS (Jeffery el al. 2014). This study evaluated the value of a single instillation ESI as treatment in DLSS, comparing outcome between both ESI and surgical decompression as well as its potential value as a predictor of surgical outcome.

The results of this clinical trial were in accordance with previous studies, confirming the safety and efficacy of ESI (Janssens el al. 2009, Liotta et al. 2016, Salmelin et al. 2019). Contrary to the results reported by Janssens and others (Janssens et al. 2009), 15.6% failed to demonstrate a clinical response in our study. We measured both the duration of the clinical effect of ESI (termed here as relapse), and the length of time it took for ESI to be effective according to owners. A clinical response to ESI took a mean of 12.9 days, with some dogs taking up to 28 days for a response to be noticeable. Relapse occurred within 6 months of ESI with a median of 2 months, longer than the previously reported median of 11 days (Janssens et al. 2009). This is compatible with reports in people suffering from low-back pain, where as many as 50% of patients will be pain-free for two weeks, with only a very limited number of cases being pain-free after 6 months (White et al.1980, Parr et al. 2009). Both values reveal a variable response of individuals to ESI,

with ESI sometimes taking longer to act or having a longer effect than previously reported in dogs (Janssens et al. 2009).

Interestingly, a subset of our population (15.6%) had a sustained, complete response to a single ESI, without relapse, with a mean follow-up time of 9.4 months. This demonstrates that a subset of DLSS affected dogs can respond to a single-instillation of ESI for a longer period of time than previously reported. Further prospective studies with more dogs and a longer follow-up time would be required in order to confirm if clinical signs do eventually relapse and to help identify factors associated with such a protracted response.

In humans, despite the frequent utilisation of ESI for treatment of lumbar radiculopathy, its efficacy and indications are still matter of debate (Parr et al. 2009, Cohen et al. 2013, Roberts et al. 2009). Instillation of steroids, when utilised as a single treatment, has been shown to be equivalent to a single instillation of bupivacaine or saline (Roberts et al. 2009). In dogs, only the effect of methylprednisolone delivered into the epidural space in dogs with DLSS has been assessed (Janssens et al. 2009). Evaluation of a placebo or lidocaine administered into the epidural space would be of great interest in dogs with DLSS given the findings in people.

The mechanism of action of ESI is still not well understood and it is most likely multifactorial. Corticosteroids can directly or indirectly inhibit the synthesis or release of pro-inflammatory mediators, alter neuromuscular junction and neuronal conductivity (namely nociceptive C-fibre conduction), and reduce oedema formation secondary to increased capillary damage and permeability (McLain et al. 2005). The direct instillation of an aqueous substance into the epidural space could lead to osmotic dilution and removal of inflammatory mediators (Wilkinson and Cohen 2013). There is also the advantage over oral medication of a more targeted corticosteroid

delivery with a reduction of systemic effects (McLain et al. 2005). In this clinical trial only one dog demonstrated evidence of suspected systemic absorption of corticosteroids by exhibiting polyuria and polydipsia. Epidural steroid injection is considered a relatively safe procedure in both dogs and humans (Parr et al. 2009, Janssens et al. 2009, Karaman 2011, Liotta et al. 2016, Salmelin et al. 2019), although severe complications secondary to an epidural injection have been reported in a dog (Remedios et al. 1996). ESI is a less-invasive and more affordable procedure than surgery. However, the need for repeated instillations can lead to cumulative costs and reduce owner compliance (Janssens et al. 2009). It also must be noted, that despite the delivery of a potent anti-inflammatory drug such as methylprednisolone over the affected region, inflammation appears to be a rare finding in cases of foraminal stenosis and secondary nerve root enlargement (Matiasek et al. 2008).

Comparison of clinical outcome in the seventeen dogs undergoing both ESI and subsequent surgical decompression, revealed that a complete response was obtained in 53% of cases (9/17) following surgery, against only 17.6% (3/17) following initial ESI (Table 1). Clinical improvement was attained following surgery in all cases, despite 29.4% (5/17) having previously failed to respond to ESI alone. In terms of owner perceived outcome, ESI was subjectively not as effective as surgical decompression in regard to improving owner assessed mobility, quality of life but particularly pain (Fig. 2). There was a statistically significant difference in reduced pain, increased mobility, and greater quality of life score between sequential modalities, which appeared subjectively more marked in the pain score, where a difference of over 3 score points was observed between both mean and median initial and post-surgical score points. This data seems to indicate that decompressive surgery might be a superior treatment to single ESI in DLSS cases.

The role of ESI as an accurate predictor of clinical or owner perceived outcome following decompressive surgery is less clear. All dogs enrolled in and completing this study, which underwent surgical decompression, showed a positive response. This was the case despite some having previously failed to respond to a single-instillation ESI. Also, some dogs responded so well to a single ESI that subsequent surgical decompression was not performed. Therefore, our initial hypothesis that a positive ESI response could indicate a successful outcome of subsequent decompression, could not be confirmed.

Needle placement confirmation for epidural injection relies on techniques such as the hanging-drop, loss-of-resistance test, pressure-waves measurement, epidurography, ultrasonography and epidural electrical stimulation (Adami and Gendron 2017, Valverde 2008). The epidural electrical stimulation method utilised in this study has been reported to possess a specificity of 93% and a sensitivity of 74% in the lumbosacral joint (Garcia-Pereira et al. 2010). Despite all epidural injections being performed by experienced clinicians, it is possible that the dogs that failed to respond to ESI may have been injected outside of the epidural space. However, no systemic side-effects (e.g.polyuria or polydipsia) were reported by the owners of those dogs.

All dogs presenting with concurrent pathologies including pelvic limb orthopaedic disease were excluded from this study. Despite not being within the scope of this study, the 84.4% short term response rate to ESI suggests that ESI may be a useful diagnostic procedure to help establish the contribution of DLSS to pelvic limb dysfunction from concurrent pathologies in dogs (e.g. acute or chronic orthopaedic disease affecting the hips or stifles).

A series of limitations exist in this study. Clinical outcome information relied on the expertise of the same people that performed the procedures, potentiating clinician bias. Owner perceived

outcome is inherently subjective, prone to caregiver placebo effect that may be impacted by the relative cost of ESI versus surgical decompression. The utilisation of a subjective numeric grading for owner perceived outcome was not based on a previously validated method.

Chapter V

CONCLUSIONS

1. Conclusions

This thesis proposed to investigate surgical management strategies and new insights on outcome of DLSS. This has been initially addressed by investigating retrospectively the population presenting signs of foraminal stenosis managed surgically by means of a lateral foraminotomy. The retrospective study performed describes the largest reported population of dogs undergoing lateral foraminotomy following a previously reported procedure (Gödde and Steffen 2007). This confirmed that foraminotomy is a safe and reliable technique that can be used to address DLSS affected dogs suffering from foraminal stenosis, leading to minimal intra-operative and post-operative complications when used either alone or in combination with dorsal laminectomy. Long-term clinical improvement was achieved in all cases despite some transient recurrences which responded to conservative therapy. Neuroforaminal entrapment may be a common cause for failure of dorsal laminectomy in the subset of patients in which this has been reported. This retrospective study demonstrates the importance of achieving an accurate diagnosis for the site of ongoing pathology in DLSS and that the lateral foraminotomy has a place in the repertoire of surgical approaches to DLSS which requires consideration when evidence of foraminal stenosis is present, confirming the initial hypothesis.

The second prospective study has investigated different treatment protocols, using a series of outcome measures, through a specifically tailored owner-assessed scoring system and follow-up consultation, aiming to assess the usefulness of a single ESI in the management of DLSS, ESI as a predictor of outcome following decompressive surgery and compare the outcomes of ESI and decompressive surgery.

The prospectively performed study confirms the previously reported efficacy of ESI as a treatment of DLSS (Janssens et al. 2009) although a positive response was not achieved in all cases. The mechanisms behind this response remain unexplained. Epidural steroid injection appears inferior to surgical decompression according to clinical and owner perceived outcome. Although surgical

decompression appears the preferable option to definitively control long-term clinical signs relating to DLSS, ESI resulted in a complete and apparently long-term sustained resolution of clinical signs in a subset of dogs. This suggests that ESI may play a role in the definitive management of DLSS cases when surgery is not an option, or indeed as an initial treatment at time of diagnosis. Response to ESI was not able to predict the short-term surgical outcome in this subset of dogs. Further studies are needed to develop a protocol to identify patients which might respond long term to ESI alone.

2. Future directions

DLSS remains a field of study in clinical veterinary neurology that requires extensive work in order to stablish a more definitive classification, treatment options and outcome measures (Jeffery et al. 2014). A definitive scoring system for DLSS, ideally based on objective means (e.g. force plate analysis) is yet to be developed despite attempts of a more inclusive scoring system encompassing clinical signs and owner impressions (Steffen at al. 2017). A direct comparison between the outcome of dogs treated by decompression and decompression combined with stabilization, or indeed clear criteria defining instability are yet to be developed.

The results of this thesis appear to be clinically relevant, by means of confirming the efficacy of the lateral foraminotomy procedure in cases with foraminal stenosis, as also demonstrating that ESI has a role in the management of DLSS particularly when surgery is not an option.

Supplementary material

1. Supplement 1

Lumbosacral - initial questionnaire

Name (dog): _____ Date: _____

1. Is your dog an agility, hunting or working dog?

Yes ☐ No ☐

2. How much daily exercise does your dog receive?

Less than 1 hour ☐
More than 1 hour ☐

3. When did you first notice the current problem? (in weeks or date it started)

_____

4. Have you noticed any of the following clinical signs in your dog (tick more than one box as appropriate):

Pain ☐
One leg lameness ☐
Both legs lameness ☐
Weakness ☐
Difficulties jumping ☐
Difficulties going up stairs ☐
Difficulties standing up ☐
Lethargy ☐
Changed laying down position ☐ (If yes please describe: _____)
Urine incontinence ☐
Faecal incontinence ☐
Feet biting ☐
Tail biting ☐
Low-tail carriage ☐
Arched back ☐
Scuffing of one or both his legs ☐
Back legs collapsing episodes ☐

1. **How mobile is your dog at the moment?**

0	1	2	3	4	5	6	7	8	9	10
☐	☐	☐	☐	☐	☐	☐	☐	☐	☐	☐

0 being not mobile at all and 10 the best he has been

2. **How painful do you consider your dog to be at the moment?**

0	1	2	3	4	5	6	7	8	9	10
☐	☐	☐	☐	☐	☐	☐	☐	☐	☐	☐

0 being pain-free and 10 being extremely painful

3. **How would your rate your dog's quality of life at the moment?**

0	1	2	3	4	5	6	7	8	9	10
☐	☐	☐	☐	☐	☐	☐	☐	☐	☐	☐

0 being poor quality of life and 10 being excellent quality of life

2. Supplement 2

Lumbosacral - second questionnaire

Name (dog): _____ Date: _____

1. **Do you think your dog is better after epidural injection?**

Yes ☐ No ☐

2. **Has your dog recovered completely? How long did it take before complete recovery occurred?**

Yes ☐ No ☐ Time (days/weeks): _____

3. **Have you noticed any of the following clinical signs in your dog, following epidural-injection (tick more than one box as appropriate):**

Pain ☐
One leg lameness ☐
Both legs lameness ☐
Weakness ☐
Difficulties jumping ☐
Difficulties going up stairs ☐
Difficulties standing up ☐
Lethargy ☐
Changed laying down position ☐ (If yes please describe: _____)
Urine incontinence ☐
Faecal incontinence ☐
Feet biting ☐
Tail biting ☐
Low-tail carriage ☐
Arched back ☐
Scuffing of one or both his legs ☐
Back legs collapsing episodes ☐

4. **How mobile is your dog at the moment?**

0	1	2	3	4	5	6	7	8	9	10
☐	☐	☐	☐	☐	☐	☐	☐	☐	☐	☐

0 being not mobile at all and 10 the best he has been

5. **How painful do you consider your dog to be at the moment?**

0	1	2	3	4	5	6	7	8	9	10
☐	☐	☐	☐	☐	☐	☐	☐	☐	☐	☐

0 being pain-free and 10 being extremely painful

6. **How would your rate your dog's quality of life at the moment?**

0	1	2	3	4	5	6	7	8	9	10
☐	☐	☐	☐	☐	☐	☐	☐	☐	☐	☐

0 being poor quality of life and 10 being excellent quality of life

3. Supplement 3

Lumbosacral - third questionnaire

Name (dog): _____ Date: _____

1. **Do you think your dog is better after surgery?**

Yes ☐ No ☐

2. **Has your dog recovered completely? How long did it take before improvement occurred?**

Yes ☐ No ☐ Time (days/weeks): _____

3. **Have you noticed any of the following clinical signs in your dog, following surgery (tick more than one box as appropriate):**

Pain ☐
One leg lameness ☐
Both legs lameness ☐
Weakness ☐
Difficulties jumping ☐
Difficulties going up stairs ☐
Difficulties standing up ☐
Lethargy ☐
Changed laying down position ☐ (If yes please describe: _____)
Urine incontinence ☐
Faecal incontinence ☐
Feet biting ☐
Tail biting ☐
Low-tail carriage ☐
Arched back ☐
Scuffing of one or both his legs ☐
Back legs collapsing episodes ☐

4. **How mobile is your dog at the moment?**

0	1	2	3	4	5	6	7	8	9	10
☐	☐	☐	☐	☐	☐	☐	☐	☐	☐	☐

0 being not mobile at all and 10 the best he has been

5. **How painful do you consider your dog to be at the moment?**

0	1	2	3	4	5	6	7	8	9	10
☐	☐	☐	☐	☐	☐	☐	☐	☐	☐	☐

0 being pain-free and 10 being extremely painful

6. **How would your rate your dog's quality of life at the moment?**

0	1	2	3	4	5	6	7	8	9	10
☐	☐	☐	☐	☐	☐	☐	☐	☐	☐	☐

0 being poor quality of life and 10 being excellent quality of life

References

Adami C, Gendron K. What is the evidence? The issue of verifying correct needle position during epidural anaesthesia in dogs. Veterinary anaesthesia and analgesia. 2017 Mar 1;44(2):212-8.

Aikawa T, Fujita H, Kanazono S, Shibata M, Yoshigae Y. Long-term neurologic outcome of hemilaminectomy and disk fenestration for treatment of dogs with thoracolumbar intervertebral disk herniation: 831 cases (2000–2007). Journal of the American Veterinary Medical Association. 2012 Dec 15;241(12):1617-26.

Axlund TW, Hudson JA. Computed tomography of the normal lumbosacral inter vertebral disc in 22 dogs. Veterinary Radiology & Ultrasound. 2003 Nov;44(6):630-4.

Bagley RS. Surgical stabilization of the lumbosacral joint. Textbook of small animal surgery. 2003:1238-43.

Baron R, Binder A, Wasner G. Neuropathic pain: diagnosis, pathophysiological mechanisms, and treatment. The Lancet Neurology. 2010 Aug 1;9(8):807-19.

Behrend, E. N., & Kemppainen, R. J. Glucocorticoid Therapy. Veterinary Clinics of North America: Small Animal Practice, 27(2). 1997 187–213.

Breit S, Giebels F, Kneissl S. Foraminal and paraspinal extraforaminal attachments of the sixth and seventh lumbar spinal nerves in large breed dogs. The Veterinary Journal. 2013 Sep 1;197(3):631-8.

Brisson BA. Intervertebral disc disease in dogs. The Veterinary clinics of North America. Small animal practice. 2010 Sep;40(5):829-58.

Burkert BA, Kerwin SC, Hosgood GL, Pechman RD, Fontenelle JP. Signalment and clinical features of diskospondylitis in dogs: 513 cases (1980–2001). Journal of the American Veterinary Medical Association. 2005 Jul 15;227(2):268-75.

Buttermann GR. Treatment of lumbar disc herniation: epidural steroid injection compared with discectomy: a prospective, randomized study. JBJS. 2004 Apr 1;86(4):670-9.

Cardy TJ, Tzounos CE, Volk HA, De Decker S. Clinical characterization of thoracolumbar and lumbar intervertebral disk extrusions in English Cocker Spaniels. Journal of the American Veterinary Medical Association. 2016 Feb 15;248(4):405-12.

Carozzo C, Cachon T, Genevois JP, Fau D, Remy D, Daniaux L, Collard F, Viguier E. Transiliac approach for exposure of lumbosacral intervertebral disk and foramen: technique description. Veterinary Surgery. 2008 Jan;37(1):27-31.

Chambers JN, Selcer BA, Oliver JE Jr. Results of treatment of degenerative lumbosacral stenosis in dogs by exploration and excision. Vet Comp Orthop Traumatol. 1988;3:130-133.

Chambers JN: Degenerative lumbosacral stenosis in dogs. Veterinary Medicine Report 1:166-180, 1989

Cohen, S.P., Bicket, M.C., Jamison, D., Wilkinson, I., Rathmell, J.P., 2013. Epidural steroids: a comprehensive, evidence-based review. Regional Anesthesia and Pain Medicine 38, 175–200.

Cuddon PA. Electrophysiology in neuromuscular disease. Veterinary Clinics: Small Animal Practice. 2002 Jan 1;32(1):31-62.

Damur-Djuric NA, Steffen F, Hässig M, Morgan JP, Flückiger MA. Lumbosacral transitional vertebrae in dogs: classification, prevalence, and association with sacroiliac morphology. Veterinary Radiology & Ultrasound. 2006 Jan;47(1):32-8.

Danielsson F, Sjöström L. Surgical treatment of degenerative lumbosacral stenosis in dogs. Veterinary Surgery. 1999 Mar;28(2):91-8.

De Decker S, Wawrzenski LA, Volk HA. Clinical signs and outcome of dogs treated medically for degenerative lumbosacral stenosis: 98 cases (2004–2012). Journal of the American Veterinary Medical Association. 2014 Aug 15;245(4):408-13.

De Haan JJ, Shelton SB, Ackerman N. Magnetic resonance imaging in the diagnosis of degenerative lumbosacral stenosis in four dogs. Veterinary surgery. 1993 Jan;22(1):1-4.

De Lahunta A, Glass E, Kent M. General sensory systems: general proprioception and general somatic afferent. Veterinary Neuroanatomy and Clinical Neurology, 4rd ed. St Louis, MO: Elsevier Saunders. 2015:237-56.

de Nies KS, Edwards RA, Bergknut N, Beukers M, Meij BP. Caudal lumbar spinal cysts in two French Bulldogs. Acta veterinaria scandinavica. 2018 Dec;60(1):14.

De Risio L, Thomas WB, Sharp NJ. Degenerative lumbosacral stenosis. Veterinary Clinics: Small Animal Practice. 2000 Jan 1;30(1):111-32.

De Risio L, Sharp NJ, Olby NJ, Muñana KR, Thomas WB. Predictors of outcome after dorsal decompressive laminectomy for degenerative lumbosacral stenosis in dogs: 69 cases (1987–1997). Journal of the American Veterinary Medical Association. 2001 Sep 1;219(5):624-8.

Evans HE, De Lahunta A. Miller's anatomy of the dog. Elsevier Health Sciences; 2013 Aug 7.

Fletcher TF, Kitchell RL. Anatomical studies on the spinal cord segments of the dog. American journal of veterinary research. 1966 Nov;27(121):1759-67.

Flückiger MA, Damur-Djuric NA, Hässig M, Morgan JP, Steffen F. A lumbosacral transitional vertebra in the dog predisposes to cauda equina syndrome. Veterinary Radiology & Ultrasound. 2006 Jan;47(1):39-44.

Forterre F, Kaiser S, Garner M, Stadie B, Matiasek K, Schmahl W, Brunnberg L. Synovial cysts associated with cauda equina syndrome in two dogs. Veterinary Surgery. 2006 Jan;35(1):30-3.

Fritsch EW, Heisel J, Rupp S. The failed back surgery syndrome: reasons, intraoperative findings, and long-term results: a report of 182 operative treatments. Spine. 1996 Mar 1;21(5):626-33.

Garcia-Pereira, F.L., Hauptman, J., Shih, A.C., Laird, S.E., Pease, A., 2010. Evaluation of electric neurostimulation to confirm correct placement of lumbosacral epidural injections in dogs. American Journal of Veterinary Research 71, 157–160.

Gödde T, Steffen F. Surgical treatment of lumbosacral foraminal stenosis using a lateral approach in twenty dogs with degenerative lumbosacral stenosis. Veterinary surgery. 2007 Oct;36(7):705-13.

Golini L, Kircher PR, Lewis FI, Steffen F. Transarticular fixation with cortical screws combined with dorsal laminectomy and partial discectomy as surgical treatment of degenerative lumbosacral stenosis in 17 dogs: clinical and computed tomography follow-up. Veterinary Surgery. 2014 May;43(4):405-13.

Gomes SA, Volk HA, Packer RM, Kenny PJ, Beltran E, De Decker S. Clinical and magnetic resonance imaging characteristics of thoracolumbar intervertebral disk extrusions and protrusions in large breed dogs. Veterinary Radiology & Ultrasound. 2016 Jul;57(4):417-26.

Hankin EJ, Jerram RM, Walker AM, King MD, Warman CG. Transarticular facet screw stabilization and dorsal laminectomy in 26 dogs with degenerative lumbosacral stenosis with instability. Veterinary Surgery. 2012 Jul;41(5):611-9.

Hanna FY. Lumbosacral osteochondrosis: radiological features and surgical management in 34 dogs. Journal of Small Animal Practice. 2001 Jun;42(6):272-8.

Harcourt-Brown TR, Granger NP, Fitzpatrick N, Jeffery ND. Electrodiagnostic findings in dogs with apparently painful lumbosacral foraminal stenosis. Journal of veterinary internal medicine. 2019 Sep;33(5):2167-74.

Hayashi N, Weinstein JN, Meller ST, Lee HM, Spratt KF, Gebhart GF. The effect of epidural injection of betamethasone or bupivacaine in a rat model of lumbar radiculopathy. Spine. 1998 Apr 15;23(8):877-85.

Indrieri RJ. Lumbosacral stenosis and injury of the cauda equina. Veterinary Clinics: Small Animal Practice. 1998 May 1;18(3):697-710.

Janssens LAA, Moens Y, Coppens P, *et al*. Lumbosacral degenerative stenosis in the dog - the results of dorsal decompression with dorsal anulectomy and nucleotomy. Veterinary and Comparative Orthopaedics and Traumatology. 2000;13(02):97-103.

Janssens L, Beosier Y, Daems R. Lumbosacral degenerative stenosis in the dog. The results of epidural infiltration with methylprednisolone acetate: a retrospective study. Veterinary and Comparative Orthopaedics and Traumatology. 2009;22(06):486-91.

Jeffery ND, Barker A, Harcourt-Brown T. What progress has been made in the understanding and treatment of degenerative lumbosacral stenosis in dogs during the past 30 years?. The Veterinary Journal. 2014 Jul 1;201(1):9-14.

Jones JC, Sorjonen DC, Simpson ST, Coates JR, Lenz SD, Hathcock JT, Agee MW, Bartels JE. Comparison between computed tomographic and surgical findings in nine large-breed dogs with lumbosacral stenosis. Veterinary Radiology & Ultrasound. 1996 Jul;37(4):247-56.

Jones JC, Shires PK, Inzana KD, Sponenberg DP, Massicotte C, Renberg W, Giroux A. Evaluation of canine lumbosacral stenosis using intravenous contrast-enhanced computed tomography. Veterinary Radiology & Ultrasound. 1999 Mar;40(2):108-14.

Jones JC, Banfield CM, Ward DL. Association between postoperative outcome and results of magnetic resonance imaging and computed tomography in working dogs with degenerative lumbosacral stenosis. Journal of the American Veterinary Medical Association. 2000 Jun 1;216(11):1769-74.

Jones JC, Inzana KD. Subclinical CT abnormalities in the lumbosacral spine of older large-breed dogs. Veterinary radiology & ultrasound. 2000 Jan;41(1):19-26.

Jones JC, Davies SE, Werre SR, Shackelford KL. Effects of body position and clinical signs on L7-S1 intervertebral foraminal area and lumbosacral angle in dogs with lumbosacral disease as

measured via computed tomography. American journal of veterinary research. 2008 Nov;69(11):1446-54.

Karaman H, Kavak GÖ, Tüfek A, Yldrm ZB. The complications of transforaminal lumbar epidural steroid injections. Spine. 2011 Jun 1;36(13):E819-24.

Kinzel S, Koch J, Stopinski T, Afify M, Krombach G, Buecker A, Küpper W. Cauda equina compression syndrome (CECS): retrospective study of surgical treatment with partial dorsal laminectomy in 86 dogs with lumbosacral stenosis. Berliner und Munchener tierarztliche Wochenschrift. 2004 Jul 1;117(7-8):334-40.

Kobayashi S, Kokubo Y, Uchida K, et al. Effect of lumbar nerve root compression on primary sensory neurons and their central branches - Changes in the nociceptive neuropeptides substance P and somatostatin. Spine. 2005a; 30(3):276–282.

Kobayashi S, Sasaki S, Shimada S, et al. Changes of calcitonin gene- related peptide in primary sensory neurons and their central branch after nerve root compression of the dog. Arch Phys Med Rehabil. 2005b;86(3): 527–533.

Kuslich SD, Ulstrom CL, Michael CJ. The tissue origin of low back pain and sciatica: a report of pain response to tissue stimulation during operations on the lumbar spine using local anesthesia. The Orthopedic clinics of North America. 1991 Apr;22(2):181-7.

Lee RK, Griffith JF, Lau YY, Leung JH, Ng AW, Hung EH, Law SW. Diagnostic capability of low-versus high-field magnetic resonance imaging for lumbar degenerative disease. Spine. 2015 Mar 15;40(6):382-91.

Lindahl O, Rexed B. Histologic changes in spinal nerve roots of operated cases of sciatica. Acta Orthopaedica Scandinavica. 1951 Jan 1;20(3):215-25.

Linn LL, Bartels KE, Rochat MC, Payton ME, Moore GE. Lumbosacral stenosis in 29 military working dogs: epidemiologic findings and outcome after surgical intervention (1990–1999). Veterinary surgery. 2003 Jan;32(1):21-9.

Liotta AP, Girod M, Peeters D, Sandersen C, Couvreur T, Bolen G. Clinical effects of computed tomography–guided lumbosacral facet joint, transforaminal epidural, and translaminar epidural injections of methylprednisolone acetate in healthy dogs. American Journal of Veterinary Research. 2016 Oct;77(10):1132-9.

Maher CO, Henderson FC. Lateral exit-zone stenosis and lumbar radiculopathy. Journal of Neurosurgery: Spine. 1999 Jan 1;90(1):52-8.

Matiasek K, Steffen F, Gödde T. Entrapped L7 dorsal root ganglia show an increased expression of calcium channel subunit alpha-2-delta (Poster Presentation). Selected research communications of the 23rd Symposium of the ESVN-ECVN Cambridge. J Vet Int Med. 2011;26(1):218–219.

Matiasek K, Steffen F, Schmahl W et al. Back to the roots – radicular pathology in foraminal stenosis (5 cases). J Vet Intern Med 2008; 22 (29): 504

Mayhew PD, Kapatkin AS, Wortman JA, Vite CH. Association of cauda equina compression on magnetic resonance images and clinical signs in dogs with degenerative lumbosacral stenosis. Journal of the American Animal Hospital Association. 2002 Nov;38(6):555-62.

McLain RF, Kapural L, Mekhail NA. Epidural steroid therapy for back and leg pain: mechanisms of action and efficacy. The Spine Journal. 2005 Mar 1;5(2):191-201.

Méheust P. A new surgical technique for lumbosacral stabilization: arthrodesis using the pedicle screw fixation. A clinical study of 5 cases. Pratique Médicale & Chirurgicale de l'Animal de Compagnie. 2000;35(3):201-7.

Meij BP, Suwankong N, van den Brom WE, et al. Tibial nerve somatosensory evoked potentials in dogs with degenerative lumbosacral stenosis. Vet Surg. 2006; 35: 168- 175.

Meij BP, Suwankong N, Van der Veen AJ, Hazewinkel HA. Biomechanical flexion–extension forces in normal canine lumbosacral cadaver specimens before and after dorsal laminectomy–discectomy and pedicle screw–rod fixation. Veterinary Surgery. 2007 Dec;36(8):742-51.

Meij BP, Bergknut N. Degenerative lumbosacral stenosis in dogs. Veterinary Clinics: Small Animal Practice. 2010 Sep 1;40(5):983-1009.

Moens NM, Runyon CL. Fracture of L7 vertebral articular facets and pedicles following dorsal laminectomy in a dog. Journal of the American Veterinary Medical Association. 2002 Sep 15;221(6):807-10.

Ness MG. Degenerative lumbosacral stenosis in the dog: a review of 30 cases. Journal of Small Animal Practice. 1994 Apr;35(4):185-90.

Oliver JJ, Selcer RR, Simpson S. Cauda equina compression from lumbosacral malarticulation and malformation in the dog. Journal of the American Veterinary Medical Association. 1978 Jul;173(2):207-14.

Ondreka N, Amort KH, Stock KF, Tellhelm B, Klumpp SW, Kramer M, Schmidt MJ. Skeletal morphology and morphometry of the lumbosacral junction in German shepherd dogs and an evaluation of the possible genetic basis for radiographic findings. The Veterinary Journal. 2013 Apr 1;196(1):64-70.

Parr AT, Diwan S, Abdi S. Lumbar interlaminar epidural injections in managing chronic low back and lower extremity pain: a systematic review. Pain Physician 2009; 12(1): 163-188.

Ramirez III O, Thrall DE. A review of imaging techniques for canine cauda equina syndrome. Veterinary radiology & ultrasound. 1998 Jul;39(4):283-96.

Rapp M, Ley CJ, Hansson K, Sjöström L. Postoperative computed tomography and low-field magnetic resonance imaging findings in dogs with degenerative lumbosacral stenosis treated by dorsal laminectomy. Veterinary and Comparative Orthopaedics and Traumatology. 2017;30(02):143-52.

Remedios AM, Wagner R, Caulkett NA, Duke T. Epidural abscess and discospondylitis in a dog after administration of a lumbosacral epidural analgesic. The Canadian Veterinary Journal. 1996 Feb;37(2):106.

Roberts ST, Willick SE, Rho ME, Rittenberg JD. Efficacy of lumbosacral transforaminal epidural steroid injections: a systematic review. PM&R. 2009 Jul 1;1(7):657-68.

Sale CS, Smith KC. Extradural spinal juxtafacet (synovial) cysts in three dogs. journal of small animal practice. 2007 Feb;48(2):116-9.

Salmelin B, Fitzpatrick N, Rose J, Driver C. Safety profile of methylprednisolone acetate epidural injection in dogs treated for lumbosacral disease. In BSAVA Congress Proceedings, Apr 1 (546-546). 2019 BSAVA Library.

Schmid V, Lang J. Measurements on the lumbosacral junction in normal dogs and those with cauda equine compression. Journal of Small Animal Practice. 1993 Sep;34(9):437-42.

Schmökel H, Rapp M. Lameness caused by an extradural lumbosacral foraminal synovial cyst in three German Shepherd Dogs. Veterinary and Comparative Orthopaedics and Traumatology. 2016;29(01):83-8.

Schwarz T, Owen MR, Long S, Sullivan M. Vacuum disk and facet phenomenon in a dog with cauda equina syndrome. Journal of the American Veterinary Medical Association. 2000 Sep 1;217(6):862-4.

Sisson AF, LeCouteur RA, Ingram JT, et al. Diagnosis of cauda equina abnormalities by using electromyography, discography, and epidurography in dogs. J Vet Intern Med. 1992;6:253-263.

Sharp NJH. and Wheeler SJ (2005). Lumbosacral Disease. In Sharp NJH and Wheeler SJ, Small Animal Spinal Disorders: Diagnosis and Surgery (2nd ed.). (pp. 181- 210). Philadelphia: Elsevier Mosby.

Sjöström L. Degenerative lumbosacral stenosis: Surgical Decompression. In D. Slatter, Textbook of Small Animal Surgery (3rd ed.). (pp. 1227-1237). 2003 Philadelphia: Saunders.

Slocum BA, Devine T. L7-S1 fixation-fusion for treatment of cauda equina compression in the dog. Journal of the American Veterinary Medical Association. 1986 Jan;188(1):31-5.

Smolders LA, Voorhout G, van de Ven R, Bergknut N, Grinwis GC, Hazewinkel HA, Meij BP. Pedicle screw-rod fixation of the canine lumbosacral junction. Veterinary Surgery. 2012 Aug;41(6):720-32.

Steffen F, Smolders LA, Roentgen AM, Bertolo A, Stoyanov J. Bone marrow-derived mesenchymal stem cells as autologous therapy in dogs with naturally occurring intervertebral disc disease: feasibility, safety, and preliminary results. Tissue Engineering Part C: Methods. 2017 Nov 1;23(11):643-51.

Steffen F. Tunnel rehab: surgery for lumbosacral foraminal stenosis in dogs. Veterinary Record. 2018 Sep 22;183(11):350-1.

Suwankong N, Meij BP, Voorhout G, De Boer AH, Hazewinkel HA. Review and retrospective analysis of degenerative lumbosacral stenosis in 156 dogs treated by dorsal laminectomy. Veterinary and Comparative Orthopaedics and Traumatology. 2008;21(03):285-93.

Suwankong N, Voorhout G, Hazewinkel HA, Meij BP. Agreement between computed tomography, magnetic resonance imaging, and surgical findings in dogs with degenerative lumbosacral stenosis. Journal of the American Veterinary Medical Association. 2006 Dec 15;229(12):1924-9.

Thomson CE, Hahn CN. Ascending somatic sensory tracts and conscious sensory systems. In: Veterinary Neuroanatomy. 1st ed. Edinburgh (UK): Elsevier-Saunders; 2012:59–66.

Togni A, Kranenburg HJ, Morgan JP, Steffen F. Radiographic and MRI characteristics of lumbar disseminated idiopathic spinal hyperostosis and spondylosis deformans in dogs. Journal of Small Animal Practice. 2014:55(7):343-9.

Valverde A. Epidural analgesia and anesthesia in dogs and cats. Veterinary Clinics of North America: Small Animal Practice. 2008 Nov 1;38(6):1205-30.

Webb AA, Pharr JW, Lew LJ, Tryon KA. MR imaging findings in a dog with lumbar ganglion cysts. Veterinary Radiology & Ultrasound. 2001 Jan;42(1):9-13.

Wilkinson I, Cohen SP. Epidural steroids for spinal pain and radiculopathy: a narrative, evidence-based review. Current Opinion in Anesthesiology. 2013 Oct 1;26(5):562-72.

Wood BC, Lanz OI, Jones JC, Shires PK. Endoscopic-assisted lumbosacral foraminotomy in the dog. Veterinary Surgery. 2004 May;33(3):221-31.

Worth AJ, Hartman A, Bridges JP, Jones BR, Mayhew JI. Effect of dorsal laminectomy and dorsal annulectomy with partial lumbosacral discectomy on the volume of the lateral intervertebral neuroforamina in dogs when the lumbosacral junction is extended. Veterinary surgery. 2017 Feb;46(2):265-70.

Worth AJ, Hartman A, Bridges JP, Jones BR, Mayhew JI. Medium-term outcome and CT assessment of lateral foraminotomy at the lumbosacral junction in dogs with degenerative lumbosacral stenosis. Veterinary and Comparative Orthopaedics and Traumatology. 2018 Jan;31(01):037-43.

Worth A, Meij B, Jeffery N. Canine Degenerative Lumbosacral Stenosis: Prevalence, Impact And Management Strategies. Veterinary Medicine: Research and Reports. 2019 :10 Pages 169-183

White AH, Derby RI, Wynne G. Epidural injections for the diagnosis and treatment of low-back pain. Spine. 1980;5(1):78-86.

Yoshizawa H, Kobayashi S, Morita T. Chronic nerve root compression. Pathophysiologic mechanism of nerve root dysfunction. Spine. 1995 Feb;20(4):397-407.